

Part 2 of 2

**REVIEW**  
OF OPTOMETRY

*A Tradition of Excellence*

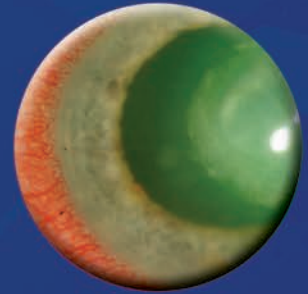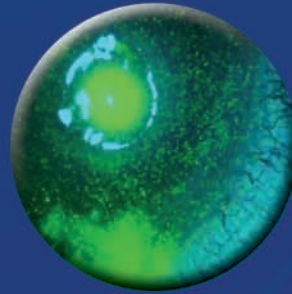
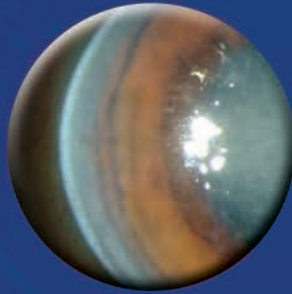
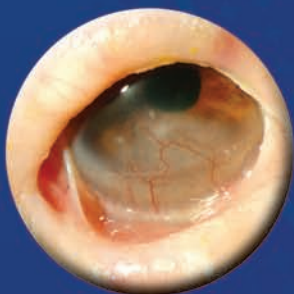Celebrating Our  
120<sup>th</sup> Year Serving the Profession  
January 2011

Sponsored by

**CIBA VISION**

Shared Passion for Healthy Vision and Better Life

# The Corneal Atlas





**Ernest Bowling, OD, FAAO**, is Center Director for VisionAmerica, a surgical co-management center in Gadsden, AL, and associate clinical editor of *Review of Cornea & Contact Lenses*. E-mail him at [drbowling@windstream.net](mailto:drbowling@windstream.net).



**Gregg Eric Russell, OD, FAAO**, is in private practice at the Marietta Eye Clinic in Atlanta. His clinical interests include dry eye, contact lenses and refractive surgery. E-mail him at [grussell@mariettaeye.com](mailto:grussell@mariettaeye.com).



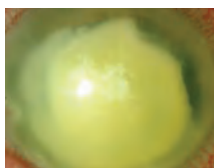**Joseph P. Shovlin, OD, FAAO**, is in private practice in Scranton, PA, associate clinical editor of *Review of Optometry* and clinical editor of *Review of Cornea and Contact Lenses*. E-mail him at [jpshovlin@gmail.com](mailto:jpshovlin@gmail.com).



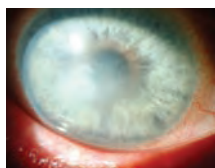**Christine W. Sindt, OD, FAAO**, is Director of Contact Lens Service and Associate Clinical Professor at the University of Iowa Hospitals and Clinics, Iowa City, IA, Chair of the AOA Contact Lens and Cornea Council, a monthly columnist for *Review of Cornea and Contact Lenses*, co-clinical editor for *Review of Optometry*, and photo editor for the Corneal Atlas. E-mail her at [christine-sindt@uiowa.edu](mailto:christine-sindt@uiowa.edu).

## Table of Contents


Bacterial .....	4
Viral .....	5
<i>Acanthamoeba</i> Keratitis .....	7
Fungal .....	8
Epithelial .....	9
Bowman's .....	11
Stroma .....	11
Endothelium .....	14
Degenerations .....	15
Mechanical .....	16
Chemical .....	18
Inflammatory .....	20



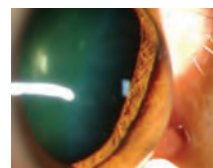
6



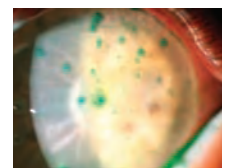
8



14



16



21

# Bacterial

## MICROBIAL KERATITIS

### Etiology

Microbial keratitis is the most visually devastating complication associated with contact lens wear. While even daily wear of contact lenses carries an increased risk for infection, extended or overnight contact lens wear is the greatest risk factor for infectious keratitis in patients choosing to wear contact lenses.<sup>1</sup> Many bacteria have been identified in contact lens related microbial keratitis, with the most common organisms cultured from bacterial ulcers being *Staphylococcus*, *Streptococcus*, *Pseudomonas* and *Moraxella*.<sup>2</sup> The gram-negative rod *Pseudomonas aeruginosa* is commonly associated with microbial keratitis in soft contact lens wear.<sup>3</sup> It is important to remember that the organisms *Neisseria gonorrhoeae*, *Listeria*, *Corynebacterium* and *Haemophilus aegypticus* do not require damage to the cornea and may invade directly through intact corneal epithelium.<sup>4</sup>

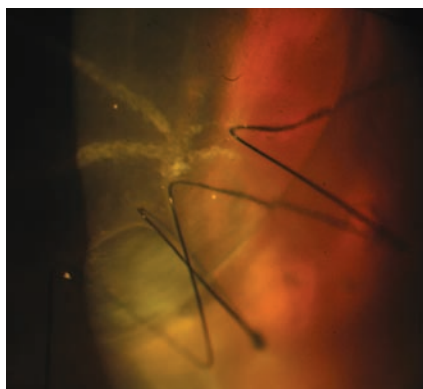### Presentation

Patients with microbial keratitis present with symptoms including decreased vision, photophobia, moderate to severe ocular pain, redness, swelling and discharge. On slit lamp examination, the critical finding is a focal white opacity in the corneal stroma with an overlying corneal epithelial defect that stains with fluorescein.<sup>2</sup> Additional findings include diffuse epithelial edema, stromal infiltration surrounding the ulceration, and mucopurulent exudation. An anterior chamber reaction and hypopyon may be present. It is important to document the depth and location of the epithelial defect and stromal infiltration. The anterior chamber should be evaluated for cells and flare and examined for a hypopyon, and the intraocular pressure should be checked.

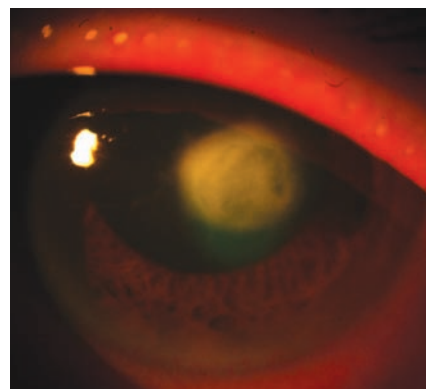
Much has been made regarding culture and sensitivity testing in cases of microbial keratitis. In general, consider cultures in ulcers greater than 1 mm to 2 mm,

#### ICD-9 Codes

- 370.00 Corneal ulcer, unspecified
- 370.01 Marginal corneal ulcer
- 370.02 Ring corneal ulcer
- 370.03 Central corneal ulcer
- 370.04 Hypopyon ulcer
- 370.05 Mycotic corneal ulcer
- 370.06 Perforated corneal ulcer
- 371.00 Corneal opacity/scar, unspecified (upon resolution)



Culture positive enterobacter corneal ulcer



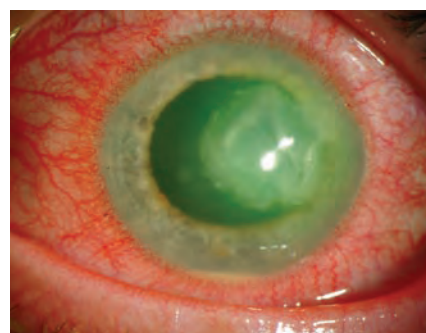Culture positive Pseudomonas corneal ulcer

defects in the visual axis, ulcers unresponsive to initial therapy, or if an unusual organism is suspected. Remember that only approximately 40% of corneal cultures identify causative pathogens. For this reason, culturing the contact lens in addition to the corneal ulcer can aid in identifying the causative organism.<sup>5</sup>

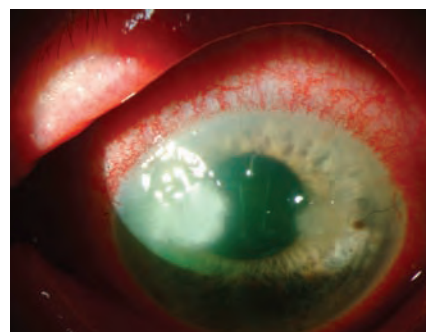### Treatment

Ulcers need to be considered infectious until proven otherwise. Therapy begins with immediate, intensive, aggressive treatment with fourth generation fluoroquinolones while awaiting lab results. Dosage is every 30 minutes for the first six hours, followed by hourly administration around the clock until improvement is noted. The use of fourth generation fluoroquinolones in the treatment of corneal ulcers is an off-label use of these medications but routinely used and no difference in efficacy with the use of fourth generation fluoroquinolone monotherapy when compared with combination therapy of fortified antibiotics has been noted.<sup>6</sup> Cycloplegic drops are valuable for patient comfort and to prevent synechiae formation in accompanying iritis.

**AVOID STEROIDS!** Especially initially. Corticosteroid treatment resulted in a statistically significant delay in corneal re-epithelialization and steroid use did not translate to a significant difference in visual acuity or infiltrate/scar size.<sup>7</sup> Infectious keratitis may worsen with topical steroid use, especially when caused by fungus, atypical mycobacteria or *Pseudomonas*. Once the cornea has re-epithelialized and the causative organism has demonstrated sensitivity to the antibiotic (usually after 72 hours of treatment), a steroid may be added to the therapeutic regimen to control persistent inflammation and reduce tissue damage.



Pseudomonas



Nocardia infection

The patient with an infectious keratitis needs to be followed daily, with careful monitoring of the findings. The antibiotic regimen should be reduced depending on the response, but should never be tapered below the minimum dose (usually q.i.d. to t.i.d.) to prevent the possibility of bacterial resistance.

#### References

1. Keay L, Stapleton F, Schein O. Epidemiology of contact-lens related inflammation and microbial keratitis: A 20-year perspective. *Eye Cont Lens* 2007;33 (6):346-353.
2. Ehlers JP, Shah CP, eds. *The Wills Eye Manual: Office and Emergency Room Diagnosis and Treatment of Eye*

Disease, 5th ed. Philadelphia: Lippincott Williams & Wilkins, 2008:62-66.

3. Green M, Apel A, Stapleton F. Risk factors and causative organisms in microbial keratitis. *Cornea* 2008; 27(1):22-7.

4. Reed WP, Williams RC. Bacterial adherence: First step in pathogenesis of certain infections. *J Chronic Dis* 1978; 31:67.

5. Das S, Sheorey H, Taylor HR, et al. Association between cultures of contact lens and corneal scraping in contact lens related microbial keratitis. *Arch Ophthalmol* 2007;125(9):1182-5.

6. Shah VM, Tandon R, Satpathy G, et al. Randomized clinical study for comparative evaluation of fourth-gen-

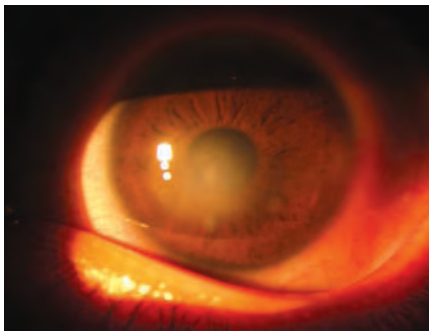
eration fluoroquinolones with the combination of fortified antibiotics in the treatment of bacterial corneal ulcers. *Cornea* 2010 Jul;29(7):751-7.

7. Srinivasan M, Lalitha P, Mahalakshmi R, et al. Corticosteroids for Bacterial Corneal Ulcers. *Br J Ophthalmol* 2009; 93(2):198-202.

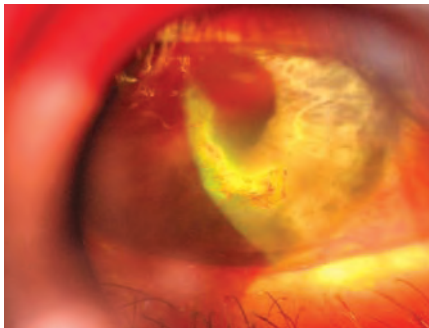
## Viral Infections

### ADENOVIRAL KERATOCONJUNCTIVITIS Etiology

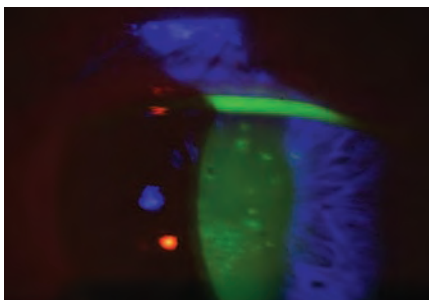
Adenoviruses produce the most common viral conjunctival infections. The most common serotypes involved are 3, 8, 19, and 37.<sup>1</sup> The condition is quite contagious and is transmitted readily in respiratory and ocular secretions, eye droppers and mascara bottles, and contaminated swimming pools. The incubation period



HSV disciform keratitis



Geographic HSV ulcer-note staining with Rose Bengal



HZK Keratitis. Coarse keratitis shown under white light

is usually 5 to 12 days, and the clinical illness is present from 5 to 15 days. Most cases of viral conjunctivitis resolve spontaneously, without sequelae, within days to weeks.

There are four forms of adenoviral conjunctivitis: Follicular conjunctivitis, pharyngoconjunctival fever, epidemic keratoconjunctivitis (EKC), and acute hemorrhagic conjunctivitis.<sup>2</sup> Follicular conjunctivitis is the mildest form of adenoviral conjunctivitis. Pharyngoconjunctival fever is the most common ocular adenoviral infection and is characterized by a combination of pharyngitis, fever, and conjunctivitis. Epidemic keratoconjunctivitis (EKC) is a more severe form of conjunctivitis and typically lasts for seven–21 days. EKC can affect the cornea with coarse keratitis and sub-epithelial infiltrates (SEIs). SEIs may last for months, affecting visual acuity. Acute hemorrhagic conjunctivitis produces a severe, painful follicular conjunctivitis with the development of tiny subconjunctival hemorrhages.

### Presentation

In general, viral infections present with redness, irritation, itching, foreign body sensation, tearing and photophobia. The condition starts in one eye and then progresses to the other a few days later. Signs include conjunctival injection and swelling. The lids may be swollen. Inferior palpebral conjunctival follicles are seen. Pinpoint subconjunctival hemorrhages and membrane formation over the palpebral conjunctiva are occasionally seen. In some cases multiple, focal infiltrates in the cornea anterior to mid-stroma may be seen. A pre-auricular lymphadenopathy is present. A rapid, in-office immunodiagnostic test using antigen detection is available for adenovirus conjunctivitis. In a study of 186 patients with acute conjunctivitis, this test had a sensitivity of 88% to 89% and a specificity of 91% to 94%.<sup>3</sup>

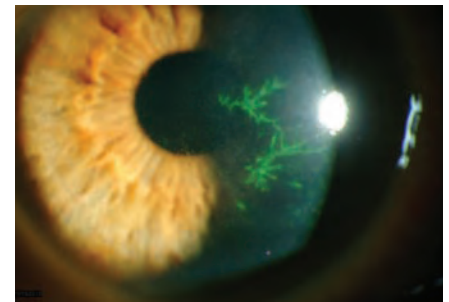### Treatment

Palliative therapy is often sufficient for most cases of adenoviral conjunctivitis: cold compresses, artificial tears and topical decongestants/antihistamines. 5% Betadine is now available as an FDA-approved product

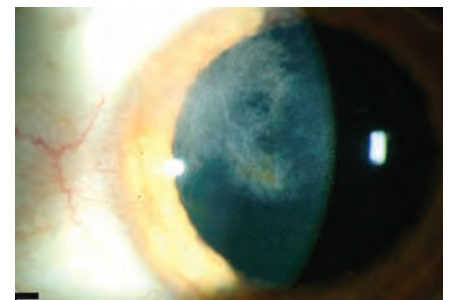
which can be used “off-label” to treat EKC. This agent has minimal toxicity when used properly and followed by saline irrigation. In vitro, povidone iodine is effective against adenovirus as well as many other infectious agents. Topical steroids are indicated when the visual axis is involved or membrane or pseudo-membrane formation is noted. Patients should discontinue contact lens wear. Avoid the use of topical and oral antibiotic or antiviral agents as these will not help resolution and may promote antibiotic resistance. Patients with adenoviral conjunctivitis need to understand that the condition

#### ICD-9 Codes

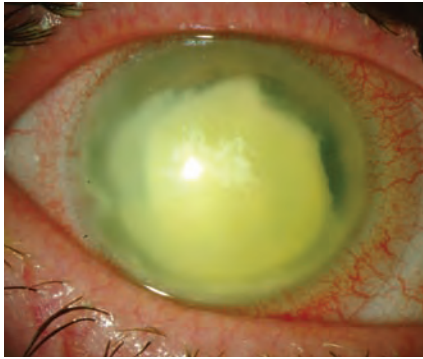
- 372.00 Unspecified conjunctivitis
- 372.02 Acute follicular conjunctivitis
- 372.03 Other mucopurulent conjunctivitis
- 372.04 Pseudomembranous conjunctivitis
- 372.11 Simple chronic conjunctivitis
- 077.1 Epidemic keratoconjunctivitis
- 077.3 Adenoviral (acute follicular)



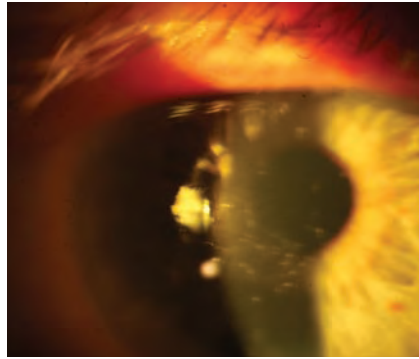
Classic presentation of herpes simplex keratitis



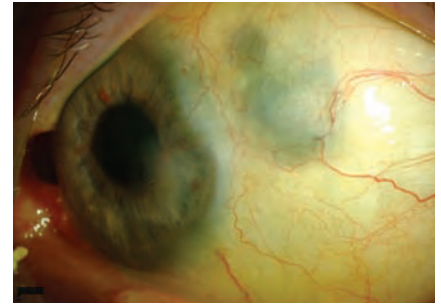
Old interstitial keratitis with ghost vessels and lipid deposits



Secondary bacterial crystalline keratopathy, after HSV keratitis, requiring PKP



HSV keratitis showing staining with NaFl



Sclerokeratitis secondary to herpes zoster

is highly contagious and should be informed of appropriate measures to reduce the risk of spreading the infection to their other eye or to other people.

### HERPES SIMPLEX KERATITIS Etiology

The herpes simplex virus (HSV) is the leading cause of vision loss in the United States. Keratitis caused by HSV is also the most common cause of cornea-derived blindness in developed nations.<sup>4</sup> The HSV is a DNA virus that resides latent in the trigeminal ganglion, only to resurrect during periods of intense stress, illness, irritation and phototoxic exposure. The disease can be present as superficial lesions, neurotrophic disease, or with deep stromal involvement.

### Presentation

Patients with HSV infection present with rapid onset unilateral pain and redness, watering and light sensitivity. Diagnosis of HSV infection is primarily based on clinical findings. The disease starts as a punctate epithelial keratitis, coalescing into the classic branching epithelial ulceration with terminal end bulbs within 24 to 48 hours.<sup>5</sup> The dendrites stain with rose Bengal or lissamine green. Corneal sensitivity may be decreased. The neurotrophic form of HSV disease is characterized by areas of intense punctate change or epithelial denudement, and can result in corneal scarring. Deep stromal lesions appear as a round, fluid filled circle. Scarring can develop in later stages with loss of stromal thickness and corneal thinning.

### Treatment

Treatment of active HSV keratitis consists of topical trifluridine 1% solution every one to two hours until no sign of active infection (lack of dendrite patterns), then five times a day for an additional seven to 10 days.<sup>6</sup> Zirgan (ganciclovir) ophthalmic gel 0.15% is indicated for the treatment of acute herpetic keratitis. The recommended dosing regimen for Zirgan is one drop in the affected eye five times per day (approximately every three

hours while awake) until the corneal ulcer heals, and then one drop three times per day for seven days.<sup>7</sup> Topical acyclovir 3% ointment (no longer commercially available but can be obtained from specialized compounding pharmacies) used five times a day as an alternative in patients with a known sensitivity to the above medications.

Oral antivirals are gaining use in the treatment of epithelial disease. Oral acyclovir 400 mg five times a day is the most common oral dosage. Alternatively, oral valacyclovir (Valtrex), a prodrug of acyclovir, can be given 500 mg three times a day. Since these drugs are cleared through the kidneys, it is critically important for the patient with renal disease that the patient's nephrologist or primary care physician and/or pharmacist be consulted regarding dosing. For a patient on long-term oral antiviral therapy for recurrent disease, check creatinine levels to insure there is no kidney damage. Normal levels of serum creatinine are approximately 0.8 to 1.4 milligrams (mg) per deciliter (dl) in adults.

Finally, consider oral antiviral prophylaxis. Oral antiviral prophylaxis has been associated with a decreased risk of recurrence of epithelial keratitis, stromal keratitis, conjunctivitis, and blepharitis due to HSV.<sup>8</sup>

#### ICD-9 Codes

- 054.43 Herpes keratitis

### HERPES ZOSTER Etiology

Herpes zoster ophthalmicus (HZO) is a recurrent infection of the varicella zoster (chickenpox) virus in the ophthalmic division of the trigeminal dermatome, most often affecting the nasociliary branch. HZO can affect any of the ocular and adnexal tissues. One in four people will contract herpes zoster in their lifetime, with this risk rising markedly after 50 years of age, especially in very elderly individuals.<sup>9</sup> Ophthalmic herpes zoster represents 10-20% of all zoster cases.<sup>10</sup>

### Presentation

HZO usually begins as an influenza-like illness characterized by fatigue, malaise, nausea and mild fever accompanied by progressive pain and skin hyperesthesia. A diffuse erythematous or maculopapular rash appears over a single dermatome three to five days later. The skin of the forehead and upper eyelid is commonly affected and strictly obeys the midline with involvement of one or more branches of the ophthalmic division of the trigeminal nerve. Involvement of the tip of the nose (Hutchinson's sign) has been thought to be a clinical predictor of ocular involvement. Although patients with a positive Hutchinson's sign have twice the incidence of ocular involvement, one third of patients without the sign develop ocular manifestations.<sup>11</sup> HZO conjunctivitis is a common ocular finding and the conjunctiva appears swollen and injected, with occasional vesicles and petechial hemorrhages. Herpes zoster keratitis manifests in five basic clinical forms:

- *Epithelial keratitis (acute or chronic).* Multiple, fine, raised intraepithelial lesions located paracentrally or at the limbus, which stain mildly with fluorescein but intensely with rose Bengal.
- *Nummular stromal keratitis.* Multiple, fine, granular infiltrates in the anterior corneal stroma.
- *Disciform keratitis.* A central, well-defined, disc-shaped area of diffuse stromal edema without vascularization. Corneal edema with anterior chamber inflammation.
- *Limbal vascular keratitis.* Limbal-vessel ingrowth and stromal edema. May be associated with adjacent episcleral or scleral inflammation.
- *Neurotrophic keratitis.* An inferior, oval epithelial defect with rolled edges. Can lead to corneal perforation.

HZO can cause either a nongranulomatous or granulomatous anterior uveitis with keratic precipitates and posterior synechiae. The diagnosis of herpes zoster disease is generally based on clinical findings.

### Treatment

All patients with ophthalmic zoster, irrespective of age or severity of symptoms,

should be prescribed oral antiviral drugs at the first sign of disease. Patients with HZO are treated with oral acyclovir (800 mg, five times daily) for seven–10 days. Early treatment with acyclovir (within 72 hours after rash onset) reduces the percentage of eye disorders in ophthalmic zoster patients from 50% to 20-30% and also lessens acute pain.<sup>12</sup> Famciclovir 500 mg three times daily for seven days or valacyclovir 1000 mg three times daily are alternatives to acyclovir. In general, the dosages for HZO are twice that for HSV infections. Palliative therapy including cool compresses, mechanical cleansing of the involved skin, and topical antibiotic ointment without steroid are helpful in treating skin lesions. Epithelial defects associated with HZO keratitis may be treated with nonpreserved artificial tears, eye ointments, punctal occlusion, pressure patching, or therapeutic soft contact lenses. Topical steroids are useful in the management of keratouveitis, interstitial

keratitis, anterior stromal infiltrates, and disciform keratitis. Topical cycloplegics prevent ciliary spasm associated with herpes zoster inflammatory disease. Aqueous suppressants and topical corticosteroids should be used to treat glaucoma associated with HZ disease.

Consider Zostavax vaccine for your patients over 60 years of age. In the landmark Shingles Prevention Study, the live attenuated Varicella Zoster Virus vaccine reduced the risk of developing shingles by 51%.<sup>13</sup>

#### References

1. Gordon, JS; Aoki, K; Kinchington, PR. Adenovirus keratoconjunctivitis. In: Pepose JS, Holland GN, Wilhelmus KR, eds. Ocular Infection and Immunity. St. Louis: Mosby;1996. pp. 877–94.
2. Yanoff M, Duker JS, eds. Ophthalmology, 3rd ed. Maryland Heights, MO, Elsevier, 2009.
3. Sambursky R, Tauber S, Schirra F, et al. The RPS adeno detector for diagnosing adenoviral conjunctivitis. Ophthalmology 2006;113:1758–64.
4. Guess S, Stone DU, Chodosh J. Evidence-based treatment of herpes simplex virus keratitis: a systematic review. Ocul Surf 2007; 5(3): 240-50.

5. Kahn BF, Pavan-Langston D. Clinical manifestations and treatment modalities in herpes simplex virus of the ocular anterior segment. Int Ophthalmol Clin 2004;44:103-33.
6. Ehlers JP, Shah CP, eds. The Wills Eye Manual: Office and Emergency Room Diagnosis and Treatment of Eye Disease, 5th Ed. Philadelphia, PA: Lippincott, Williams and Wilkins, 2008.
7. Zirgan package insert. Bausch & Lomb Pharmaceuticals.
8. Young RC, Hodge DO, Liesegang TJ, et al. Incidence, recurrence, and outcomes of herpes simplex virus eye disease in Olmsted County, Minnesota, 1976-2007: the effect of oral antiviral prophylaxis. Arch Ophthalmol 2010;128(9):1178-83.
9. Johnson RW, Bouhassira D, Kassianos G, et al. The impact of herpes zoster and post-herpetic neuralgia on quality-of-life. BMC Med 2010;8:37.
10. Ragazzino MW, Melton LJ 3rd, Kurland LT, et al. Population-based study of herpes zoster and its sequelae. Medicine (Baltimore) 1982;61:310-16.
11. Harding SP, Lipton JR, Wells JC. Natural history of herpes zoster ophthalmicus: predictors of postherpetic neuralgia and ocular involvement. Br J Ophthalmol 1987;71:353-58.
12. Cobo LM, Foulks GN, Liesegang T, et al. Oral acyclovir in the treatment of acute herpes zoster ophthalmicus. Ophthalmology 1986; 93:763-70.
13. Oxman MN, Levin MJ, Johnson GR, et al. A vaccine to prevent herpes zoster and postherpetic neuralgia in older adults. N Engl J Med 2005; 352:2271-84.

## Acanthamoeba Keratitis

### Background

*Acanthamoeba* keratitis can be severe and vision-threatening. It was first recognized in contact lens wearers in the early 1970s, and contact lens wear is thought to be associated with 80% of the cases.<sup>1,2</sup> Symptom onset is greatest during the summer months. *Acanthamoeba* species are found in virtually every environment. These protozoa are ubiquitous in the soil, dust, lakes, rivers, hot tubs and salt water. They have been isolated from heating, venting and air conditioner units (HVAC), humidifiers, dialysis units and contact lens paraphernalia. *Acanthamoeba* have been found in the nose and throat of healthy people as well as those with compromised immune systems. Contact lens wear and poor lens hygiene are often singled out as the biggest risk factors for *acanthamoeba* keratitis. The true incidence is not known; however, it is thought to be rare; affecting approximately 1.65-2.01 per million contact lens wearers per year in the United States.<sup>3</sup> However, it has been reported as high as 1/30000 contact lens wearers per year outside the United States.<sup>4</sup>

### Etiology

There are more than 20 different species, several of which are known to cause infections in humans, including *A. culbertsoni*, *A. polyphaga*, *A. castellanii*, *A. healyi*, (*A. astronyxis*), *A. hatchetti* and *A. rhysodes*. *A. castellanii* is the most common amoeba associated with corneal infec-

tion. The life cycle of these organisms is comprised of two stages, trophozoite and cystic forms. Trophozoites bind to and desquamate the corneal epithelium. They secrete a variety of proteases, which facilitate the dissolution of the corneal stroma.<sup>5</sup> When environmental conditions become unfavorable, the organism converts to a dormant cystic form, which is able to survive many years. These double walled cysts are highly resistant to killing by desiccation, freeze/thaw cycles, irradiation, chlorination levels and antimicrobial agents.

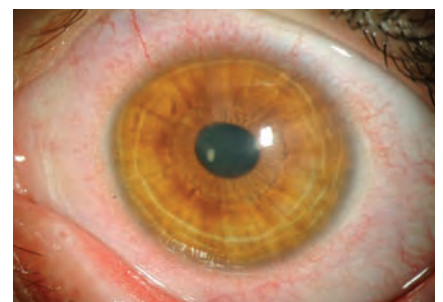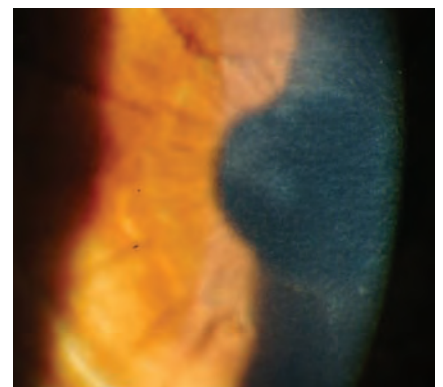
Co-infection with bacteria or fungi is common, providing food for amoeba.

### Presentation

*Acanthamoeba* keratitis presents with pain (ranging from mild foreign body sensation to severe pain), photophobia, decreased vision, injection, irritation, tearing and a protracted clinical course. The patient often presents with a unilateral red eye, where the pain is disproportionately worse than one would surmise from the clinical appearance. Early corneal findings include irregular epithelium, punctate epithelial erosions, microcystic edema, perilimbal injection and dendritiform epithelial lesions. The dendritiform lesions often resemble those of herpes simplex keratitis, however, the AK lesions appear edematous and necrotic rather than frank ulcerations.

A ring infiltrate is classically thought of as the defining sign of *acanthamoeba*

keratitis; however, it tends to form four-eight weeks after onset of symptoms and is rarely the presenting sign. Radial perineuritis (perhaps explaining the intense pain) may be seen on slit lamp examination or confocal microscopy. Unchecked, there may be progressive corneal thinning and risk of perforation. Up to 40% of



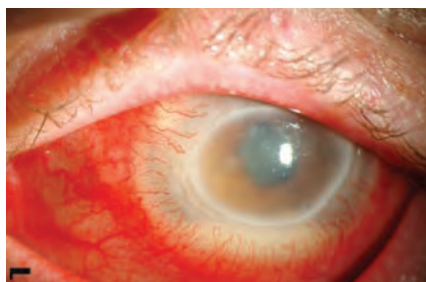Early *Acanthamoeba* keratitis

patients may have mild to severe anterior uveitis. Scleritis has been reported in patients with *Acanthamoeba* keratitis; however, the scleral inflammation was attributed to an immune-mediated response to necrotic organisms and was not believed to be the result of active infection.<sup>6-8</sup>

Severe glaucoma has been associated with *acanthamoeba* keratitis secondary to an inflammatory angle-closure mechanism, apparently without direct infiltration of the organism.<sup>9</sup>

### Treatment

Diagnosis largely depends on the ability to visualize the organism. Definitive diagnosis is made by corneal scrapings. Confocal microscopy is clinically useful to quickly identify the organism in vivo. Attempts to culture the organism is time-consuming and expensive, often with poor yields. Differential diagnosis includes herpetic keratitis, bacterial keratitis, toxic keratopathy (solution related), stem cell failure, fungal keratitis, severe dry eye and contact



Advance keratitis with stromal involvement and hypopyon

lens related corneal oxygen deficiency.

Debridement, particularly early in the disease, will reduce the number of organisms and deprive the *Acanthamoeba* of its food supply.<sup>10</sup> Cationic antiseptic agents, such as chlorhexidine 0.02% and polyhexamethyl biguanide 0.02%, are generally considered primary medical treatments. Biguanides disrupt the phospholipid structure of cell membranes. Aromatic diamides (Brolene) directly affect the amoebas nucleic acids and are thought to have a synergistic affect with the biguanides. There is a risk of significant corneal epithelial toxicity with q1-2h dosing.<sup>11,12</sup> Corticosteroids are used to treat associated uveitis or scleritis; however, this should be done with extreme caution because trophozoite proliferation has been observed when exposed to steroids.<sup>13</sup> Penetrating keratoplasty (PKP) may be necessary for tectonic or optical corneal rehabilitation. In most situations, PKP is postponed until resolution of infection. There may be residual dormant cysts in the peripheral cornea, even in a cornea that appears quiet, which may incite infection after graft. After corneal transplant, protective, maintenance doses of medication should be used to help prevent the recurrence of the *Acanthamoeba* infection.<sup>14</sup>

### ICD-9 Codes

- 370.02 Ring corneal ulcer
- 370.40-006.8 Keratoconjunctivitis

### Recommendations:

- Avoid swimming with contact lenses on.
- Showering in contact lenses may increase risk of infection.<sup>15</sup>

- Careful following of recommended lens care systems.

### References:

1. Jones DB, Visvesvara GS, Robinson NM. *Acanthamoeba* polyphaga keratitis and *Acanthamoeba* uveitis associated with fatal meningoencephalitis. Transactions of the ophthalmological societies of the United Kingdom 1975, 95(2):221-232.
2. Illingworth CD, Cook SD, Karabatsas CH, Easty DL. *Acanthamoeba* keratitis: risk factors and outcome. Br J Ophthalmol. 1995 Dec;79(12):1078-82.
3. Schaumberg DA, Snow KK, Dana MR. The epidemic of *Acanthamoeba* keratitis: where do we stand? Cornea. 1998 Jan;17(1):3-10. Review.
4. Seal DV. *Acanthamoeba* keratitis update-incidence, molecular epidemiology and new drugs for treatment. Eye. 2003 Nov;17(8):893-905. Review.
5. Investigative Ophthalmology & Visual Science, July 2005, Vol. 46, No. 7.
6. Lee GA, Gray TB, Dart JK, et al. *Acanthamoeba* sclerokeratitis: treatment with systemic immunosuppression. Ophthalmology. 2002;109:1178-1182.
7. Garner A. Pathogenesis of *Acanthamoeba* keratitis: hypothesis based on a histological analysis of 30 cases. Br J Ophthalmol. 1993;77:366-370.
8. Lindquist TD, Fritsche TR, Grutzmacher RD. Scleral ectasia secondary to *Acanthamoeba* keratitis. Cornea. 1990;9:74-76.
9. Kelley PS, Dossey AP, Patel D, Whitson JT, Hogan RN, Cavanagh HD. Secondary glaucoma associated with advanced *Acanthamoeba* keratitis. Eye Contact Lens. 2006 Jul;32(4):178-82.
10. Lindquist TD. Treatment of *Acanthamoeba* keratitis. Cornea. 1998 Jan;17(1):11-6.
11. Seal D. Treatment of *Acanthamoeba* keratitis. Expert Rev Anti Infect Ther. 2003 Aug;1(2):205-8. Review.
12. Hammersmith KM. Diagnosis and management of *Acanthamoeba* keratitis. Curr Opin Ophthalmol. 2006 Aug;17(4):327-31.
13. McClellan K, Howard K, Niederkorn JY, Alizadeh H. Effect of steroids on *Acanthamoeba* cysts and trophozoites. Invest Ophthalmol Vis Sci. 2001 Nov;42(12):2885-93.
14. Visvesvara GS, Stehr-Green JK. Epidemiology of free-living amoeba infections. The Journal of protozoology 1990, 37(4):25S-33S.
15. Joslin, CE, Tu, EY, Stayner L, Davis F. The association between *Acanthamoeba* keratitis and showering with contact lenses. Paper presented at the American Academy of Optometry October 22, 2008.

## Fungal Keratitis

Fungal keratitis is relatively rare in the United States (approximately 5 to 10 percent of reported cases), although it accounts for up to 50 percent of ulcerative keratitis elsewhere in the world. Fungal keratitis is usually associated with a history of ocular trauma,<sup>1</sup> ocular surface disease,<sup>2</sup> or topical steroid use.<sup>3</sup> There has been a lot of attention focused on the recent epidemic of fungal keratitis in soft contact lens wearers in 2005 and 2006,<sup>1,4</sup> however a recent review indicates the number of fungal keratitis cases associated with contact lens wear has been steadily increasing the past twenty years.<sup>5</sup>

### Etiology

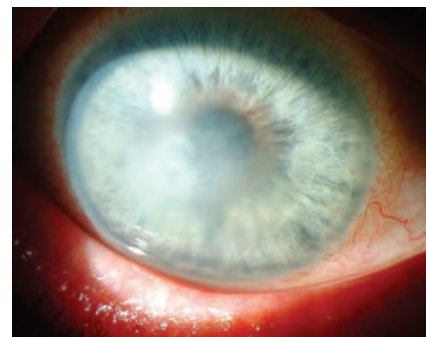Fungi require an epithelial defect for corneal penetration. Once the epithelium has been violated, the present fungi can multiply and cause severe tissue damage. Up to

30 percent of fungal keratitis cases may be associated with bacterial co-infection. Risk factors for the development of fungal keratitis include ocular trauma, topical corticosteroids, systemic immunosuppression, penetrating or refractive surgery, chronic keratitis (vernal/atopic keratitis and neurotrophic ulcers) and contact lens wear with certain lens solutions.

### Presentation

Patients present with pain, photophobia, injection, tearing and possible discharge; however, the degree of symptoms may vary. In some cases, the progression of symptoms may be slow, while in others it may move very quickly. Corneal infiltrates tend to have feathery borders, are generally grayish-white and may have satellite lesions. Larger infiltrates are associated with poor visual prognosis. The

epithelium is usually raised, and at times may be intact, over the infiltrate. An epithelial defect, anterior chamber reaction or hypopyon may be present.



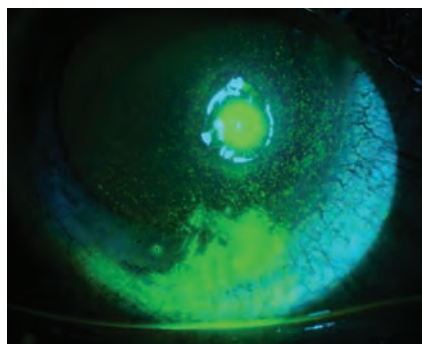
Acute necrotizing fungal keratitis after herpetic infection

Diagnosis may be difficult based on clinical examination alone. Confocal microscopy may reveal hyphae in filamentary fungal disease such as *Aspergillus* or *Fusarium*, or budding yeast forms such as *Candida*.<sup>6,7</sup> Fungal cultures are the gold standard for diagnosis.<sup>8</sup> Corneal scrapings and cultures may be positive in up to 90 percent of initial scrapings. Most fungi grow well in blood agar or Sabouraud dextrose agar as culture media. Growth usually occurs within 3 or 4 days but can take as long as 4 to 6 weeks.<sup>9</sup> Gram and Giemsa stains or potassium hydroxide (KOH) wet mounts are useful for identifying fungal elements. Polymerase chain reaction (PCR) is another diagnostic tool. Results from clinical studies suggest that PCR is more sensitive than culture as a diagnostic aid in ocular fungal infections and is also much faster. Results are known within 24 hours. However, PCR is associated with a high false-positive rate.<sup>8</sup> If there is strong suspicion of fungus and other tests are negative, biopsy may be required.

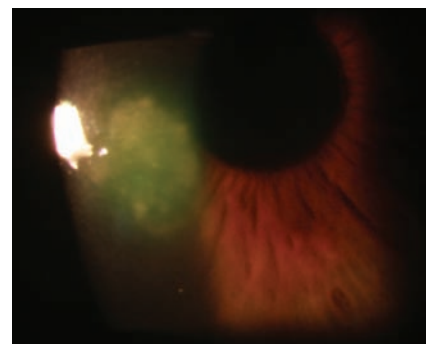
### Treatment

Topical natamycin 5% or topical amphotericin B 0.15% is first-line therapy for symptoms of suspected superficial fungal keratitis.<sup>8</sup> Natamycin is currently the only topical ophthalmic antifungal compound approved by the FDA.<sup>10</sup> It penetrates the cornea well after topical administration and is the drug of choice for fungal keratitis. Amphotericin B, because of its numerous toxicities, is administered as a second-line treatment to natamycin. Recommended dosage is 1 mg/kg/day intravenously or topically in 0.15% to 0.3% solution every 30 to 60 minutes. Side effects can include renal toxicity, headaches, fevers, chills and anorexia.<sup>10</sup> As is the case for most anterior segment injuries and infections, cycloplegics should be dispensed to improve patient comfort. In addition to standard therapy for fungal keratitis, Voriconazole (topical and oral) has also been successfully used to impart a clinical cure.

Mechanical debridement of the corneal epithelium may aid in penetration of topical medication into the stroma while providing a specimen for histopathological stains and evaluation. Therapeutic penetrating keratoplasty is often required to restore



Fungal keratitis related to contact lens wear



Fungal ulcer

vision impairment due to corneal scarring. Despite maximum pharmacologic therapy, early transplant during active disease may be required early in cases of perforation or near perforation.<sup>11</sup> As many as 27% of patients with ocular fungal infections can require corneal transplants.<sup>2</sup>

The use of topical steroids is detrimental in the treatment of fungal keratitis.<sup>12</sup> Extreme caution should be used with steroids until a sufficient amount of time for clinical stabilization has been achieved because steroids reduce the patient's immune ability to eliminate infection.<sup>13</sup>

### Recommendations

- Early on, the patient may present with no more than a "gritty" foreign body sensation with only a small, indistinct infiltrate.
- Fungal keratitis is commonly confused with bacterial keratitis. There should be a high level of suspicion of fungal agents if the lesions do not resolve/improve despite antibiotic therapy.
- Steroids will worsen/exacerbate the disease and should not be used in suspected fungal infections.
- Optimal contact lens care. Nearly all of the cases of contact lens-related fungal keratitis reported from a University of Florida study showed poor contact lens care.<sup>14</sup>

### References:

1. Chang DC, Grant GB, O'Donnell K, et al. Multistate outbreak of *Fusarium* keratitis associated with use of a contact lens solution. *JAMA* 2006; 296(8): 953-63.
2. Rosa RH Jr, Miller D, Alfonso EC. The changing spec-

trum of fungal keratitis in south Florida. *Ophthalmology* 1994; 101: 1005-1113.

3. Wong TY, AuEong KG, Chan WK, et al. *Fusarium* keratitis following the use of topical anti biotic-corticosteroid therapy in traumatized eyes. *Ann Acad Med Singapore* 1996; 25: 862-865.
4. Khor WB, Aung T, Saw SM, et al. An outbreak of *Fusarium* keratitis associated with contact lens wear in Singapore. *JAMA*. 2006;295(24):2867-73.
5. Tuli SS, Iyer SA, Driebe WT. Fungal keratitis and contact lenses: an old enemy unrecognized or a new enemy on the block? *Eye Cont Lens* 2007; 33 (6): 415-417.
6. Kaufman SC, Musch DC, Belin MW, et al. Confocal microscopy: a report by the American Academy of Ophthalmology. *Ophthalmology* 2004; 111(2): 396-406.
7. Klont RR, Eggink CA, Rijs AJ, et al. Successful treatment of *Fusarium* keratitis with cornea transplantation and topical and systemic voriconazole. *Clin Infect Dis* 2005; 40(12): 110-112.
8. Hu WS, Fan VC, Koonapareddy C, et al. Contact lens-related fusarium infection: case series experience in New York City and review of fungal keratitis. *Eye Cont Lens* 2007; 33 (6): 322-328.
9. Thomas PA. Current perspectives on ophthalmic mycoses. *Clin Microbiol Rev* 2003; 16: 730-797.
10. O'Brien TP. Therapy of ocular fungal infections. *Ophthalmol Clin North Am* 1999; 12: 33-50.
11. Winchester K, Mathers WD, Sutphin JE. Diagnosis of *Aspergillus* keratitis in vivo with confocal microscopy. *Cornea* 1997; 16(1): 27-31.
12. O'Day DM, Ray WA, Robinson RD. Efficacy of anti-fungal agents in the cornea. II. Influence of corticosteroids. *Invest Ophthalmol Vis Sci* 1984; 25: 331-335.
13. Krachmer JH, Mannis MJ, Holland EJ. *Cornea*, 2nd Edition, Vol. 1. Philadelphia: Elsevier Mosby, 2005. pp.1101-1113.
14. Iyer SA, Tuli SS, Wagoner RC. Fungal keratitis: Emerging trends and treatment outcomes. *Eye Cont Lens* 2006; 32: 267-271.

### ICD-9 Codes

- 370.05 Mycotic corneal ulcer
- 370.04 Hypopyon corneal ulcer

## Epithelial

The corneal epithelium serves a variety of roles, including serving as the primary mode of protection for the corneal surface and as the interface tissue between the corneal stroma and the tear film. Derived from surface ectoderm, it can be best described as a nonkeratinized stratified squamous layer possessing

many of the same properties of regeneration after injury and, fortunately enough, recovers in rapid fashion. For purposes of brevity, the corneal epithelium consists of deep columnar cells attached to the anterior limiting lamina (or Bowman's membrane), midlayer polygonal cells, and surface wing cells all bound

together through a variety of tight adhesions. The typical epithelial layer is approximately 50 microns thick. During cell division, the epithelial cells migrate and flow more anteriorly towards the surface, ultimately losing their nuclei and becoming "wafer" thin.

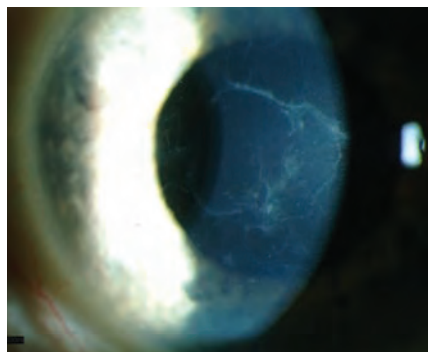
Corneal abrasions are one of the most



common forms of ocular trauma presenting to an optometric clinic. Damage to the corneal epithelium and its subsequent repair is influenced by a variety of factors, including the presence of physical conditions such as diabetes, Sjögren's or other tear chemistry altering illness, corneal denervation, lagophthalmus, recurrent corneal erosions, and basement membrane degenerations or dystrophies. Most epithelial trauma will recover within three to five days as the epithelial cells slide over to cover adjacent damage. Large or total abrasions can take significantly longer to heal. Careful attention needs to be paid to the size, position, and depth of the abrasion and whether or not any signs of infiltrate are present. Fluorescein dye should be instilled to measure the abrasion and monitor its improvement; for deeper abrasion it's imperative to assess for risk of perforation and check for Seidel's sign. Should either of these be detected, prompt medical comanagement should be initiated. Though any abrasion can predispose to future erosions, those caused by paper, fingernails or tree branches are more commonly associated with recurrent erosions and the patient should be treated and educated accordingly. Sodium chloride eyedrops and ointments, such as Muro 128 5%, are advised.

There are a variety of corneal epithelial dystrophies. Almost all are considered recessive in nature and can cause the patient symptomatic visual distortion in the form of irregular astigmatism or intermittent pain secondary to recurrent erosions.

Epithelial basement membrane dystrophy (EBMD), also known as anterior basement membrane or Cogan's dystrophy, is described as hereditary in nature, bilaterally presenting, and progressive.<sup>1</sup> Typically, EBMD can be visualized using vital dyes such as fluorescein and a wratten filter and looking for areas of discrete negative staining, as well as irregularity on the corneal topography. Typically these patients will have reduced acuity which can be improved with a rigid gas permeable trial lens.



Epithelial basement membrane dystrophy



Epithelial microcysts of Cogan's

Subepithelial mucinous corneal dystrophy is a very rare autosomal dominant condition characterized by frequent recurrent erosions in the first decade of life followed by progressive vision loss. The lesions involved the entire cornea, but are typically found centrally.<sup>2</sup>

Meesman's corneal dystrophy is a bilateral autosomal dominant disorder that generally appears early in life as epithelial microcysts in the first decade of life. Patients may remain asymptomatic for years, until epithelial erosions associated with rupture of the microcysts produce symptoms, such as impaired visual acuity, pain and photophobia.<sup>3</sup>

Lisch epithelial dystrophy (LECD) is a relatively new corneal disorder that was first described in 1992.<sup>4</sup> It is unusual because it is linked to the X chromosome. It is a gelatinous, whorl-like corneal dystrophy associated with surface deposition and appears as epithelial microcysts on retroillumination. It typically begins in childhood, sparing the center of the cornea. As the opacities progress toward the center they can decrease acuity but are not associated with recurrent erosions.<sup>5</sup> Gelatinous drop-like corneal dystrophy is a rare corneal presentation associated with surface deposition thought to be caused by a mutation of the M1S1 gene.<sup>6</sup> Typically associated with Japanese background, the condition has been noted in other parts of the world and characterized by severe visual impairment.

### Pearls

- Never use a bandage contact lens with corneal trauma that might be at risk for fungal infection. For instance, caution should be used with a patient presenting to the office with a tree branch injury to the cornea.
- Consider using a stiffer modulus soft contact lens for corneal irregularities in the corneal visual axis. Stiffer designs can drape over irregular zones and dampen the effects of irregular astigmatism.
- For patients considering cataract surgery AND possessing significant EBMD

in the visual axis, consider a targeted epithelial debridement, particularly if located near the patients' visual axis.

- For patients with EBMD, Meesman's, and Reis-Buckler's, consider the use of bandage soft lenses for episodes of recurrent erosion. Furthermore, encourage the use of nightly hyperosmotic ointments to limit intermittent nightly erosions.

### Treatment-Trauma

The treatment will depend upon the extent and presentation of the injury. In cases where there are irregular, ragged edges of epithelial tissue, it is essential to debride that tissue. Antibiotic drops can be dosed from qid to q1h depending on the size and depth of the injury, along with a cycloplegic agent bid-qid for photophobia. A bandage contact lens can be extremely beneficial to promote reepithelialization and improve patient comfort.

#### ICD-9 Codes

- 918.00 Corneal Abrasion
- 367.22 Irregular astigmatism
- 371.42 Recurrent erosion of cornea
- 371.51 Meesman's
- 371.52 EBMD

### Treatment-Dystrophies and Degenerations

EBMD treatment depends on the level of visual performance and patient discomfort. For mild presentations, the patient can use artificial tears and hyperosmotic drops and/or ointments. Ointment at bedtime is especially helpful for those patients having difficulty with overnight erosions. For patients with blurred vision due to irregular astigmatism, a soft, rigid or hybrid contact lens can be utilized. If these treatments are unsuccessful, the faulty epithelium can be debrided by diamond burr keratectomy, phototherapeutic keratectomy (PTK), or anterior stromal micropuncture (ASM). Treatment of the other epithelial dystrophies need to be considered on a case-by-case basis where treatment ranges from symptomatic relief with lubrication, Muro 128, and bandage contact lenses to more advanced treatments including debridement, PTK, and penetrating and lamellar keratoplasty. However, there is a risk of the dystrophy recurring within the graft. All tests should be medically necessary and be important for the management of the case.

All tests should have some type of interpretation of findings.

- Corneal topography—useful for cases of epithelial irregularity involving visual axis.
- Anterior segment photography—useful for documenting presence and extent of

surface changes. Tear film performance tests – Shirmer’s I or II, tear break up time, and phenol red test.

#### References:

1. <http://emedicine.medscape.com/article/1193945-overview>.
2. Feder RS, Jay M, Yue By, Stock EL, O’Grady RB, Roth SL.

- Subepithelial mucinous corneal dystrophy. Clinical and pathological correlations. Arch Ophthalmol 1993; 111: 1106-14.
3. Jalbert I, Stapleton F. Management of symptomatic Meesmann dystrophy. Optom Vis Sci. 2009; 86: E1202-06.
4. Lisch W, Steuhl KP, Lisch C, Weidle EG, Emming CT, Cohen KL, Perry HD. A new, band-shaped and whorled microcystic dystrophy of the corneal epithelium. Am J Ophthalmol. 1992; 114: 35-44.

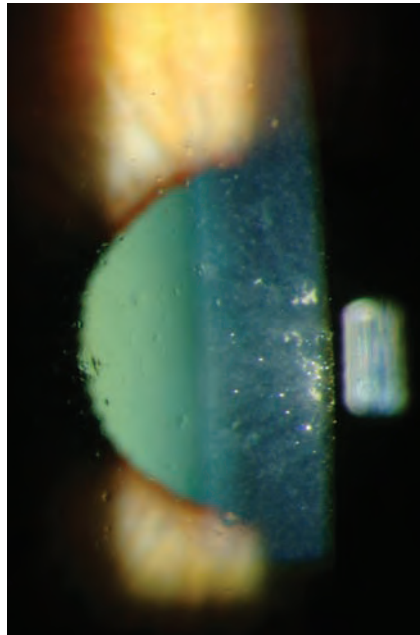
5. Aldave A, Sonmez B. Elucidating the molecular genetic basis of the corneal dystrophies. Arch Ophthalmol 2007;125(9):172-186.
6. Ha NT, Fujiki K, Hotta Y, Nakayasu K, Kanai A. Q118X mutation of M1S1 gene caused gelatinous drop-like corneal dystrophy: the P501T of BIGH3 gene found in a family with gelatinous drop-like corneal dystrophy. Am J Ophthalmol 2000; 130: 119-20.

## Bowman’s

### REIS-BUCKLERS (CORNEAL DYSTROPHY OF BOWMAN LAYER TYPE 1)

Gray, hazy, reticular deposits (crystallization) typify this Bowman’s layer dystrophy.<sup>1,3</sup> The deposits will generally form symmetrical patterns in each eye and can easily be detected at the slit lamp. The opacities cause an elevation of the surface epithelium and often create a visual disturbance by affecting surface epithelium as well as underlying stromal areas of the cornea.<sup>1</sup> It is believed to be an autosomal dominant inherited corneal dystrophy associated with mutations in the TGFBI gene and in some cases with R124L and G623D mutations.<sup>1,3</sup> Onset generally occurs by the first decade of life. This dystrophy is quite rare and its incidence is unknown.<sup>1</sup>

Patient history and symptoms will invariably include recurrent corneal erosion (traumatic or spontaneous), pain, light sensitivity and visual disturbance/distortion. The episodes of recurrent erosion tend to occur multiples times each year.<sup>2</sup> A severe disruption of the basal epithelial cells and their stromal attachments accounts for the frequent erosions. The epithelium is loosely attached since a basement membrane is focally absent.<sup>2</sup> After age 30, the erosions tend to become infrequent, but acuity continues to decline due to increased superficial corneal opacification.<sup>3</sup> Early reticular superficial opacity will advance to a honeycomb, fishnet pattern of the central and mid-peripheral cornea with prominent corneal nerves. An increased corneal thickness, irregular astigmatism and decreased corneal sensation are hallmarks of the corneal malady.<sup>1,2,4</sup>



Reis-Bucklers

Treatment and management includes topical palliative therapy to reduce the frequency of recurrent corneal erosion that includes artificial tears, epithelial debridement (manual or laser) for the recurrent erosions, and keratectomy or keratoplasty (lamellar or penetrating) for visual restoration.<sup>2</sup> Recurrence of this anterior corneal dystrophy is not uncommon. Over-the-counter pain-relievers, lubricants, NSAIDs and cycloplegics can be used for pain management when necessary.<sup>4</sup> There are no systemic treatments for this dystrophy.

### Recommendations

This condition must be differentiated from several anterior stromal conditions. To add to the confusion anterior membrane dystrophy of Grayson and Wilbrandt and the honeycomb dystrophy of Thiel and Behnke may represent clinical variants of Reis-Bucklers dystrophy.<sup>2</sup>

Management of the epithelial erosion poses the major problem earlier in life.

When opacification of the cornea impairs vision significantly, superficial keratectomy may improve vision. Advanced cases require lamellar or full thickness grafting but recurrence is common. Over the past decade, researchers using molecular genetics have redefined dystrophies of Bowman’s layer to include two distinct entities, or Reis-Bucklers and Thiel-Behnke.<sup>1</sup>

#### ICD-9 Codes

- 371.52 other anterior corneal dystrophy
- 371.42 recurrent corneal erosion
- 371.0 corneal scar and opacity code range

#### References

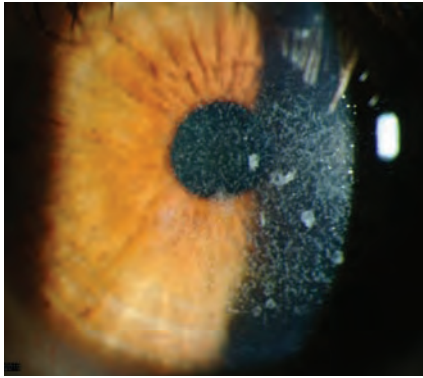
1. Bushley DM, Afshari NA:Reis-Bucklers Corneal Dystrophy. IN:Roy FH, Fraunfelder FW and Fraunfelder FT: Current Ocular Therapy. Saunders/Elsevier, New York, 2008, pp. 391-2.
2. <http://dro.hs.columbia.edu/reisbucklers.htm> (Digital Reference of Ophthalmology Corneal & External Diseases, 2003).
3. Laibson PR: Anterior Corneal Dystrophies and Corneal Erosions. IN: Leibowitz HM: Corneal Disorders: Clinical Diagnosis and Management. WB Saunders Co, New York, 1984, pp 222-4.
4. [http://legacy.revoptom.com/index.asp?page=2\\_13021.htm](http://legacy.revoptom.com/index.asp?page=2_13021.htm) (Review of Optometry On-line).

## Stroma

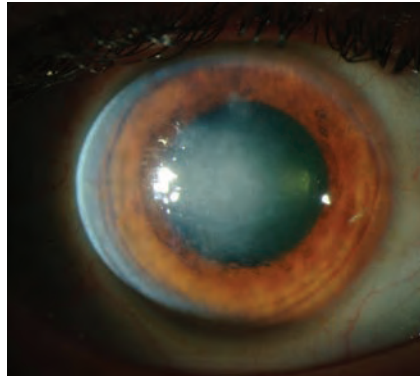
The stroma makes up the bulk of the corneal structure and is composed mainly of water, collagen and keratocytes. It is the specific arrangement of the tightly bound collagen fibers in the stroma that

allow for the transparency of the cornea, as well as provide mechanical strength. Descemet’s membrane is a thick basement membrane that is located at the posterior portion of the stroma. Four

corneal dystrophies, including granular, lattice, Avellino, and Reis-Bückler, have been linked to a mutation in the Transforming Growth Factor Beta 1 gene (TGF-1), also known as the BIGH3 gene.<sup>1</sup>



Granular corneal dystrophy



Retro illumination of advanced Fuch's dystrophy

## Types of Stromal Dystrophies

Lattice corneal dystrophy (LCD) is the most common of the stromal dystrophies. It has an autosomal dominant pattern of inheritance and appears after the first decade of life as a linear branching pattern that affects the central cornea and can increase over time. LCD is associated with a genetic mutation in the *BIGH3* gene, resulting in deposits of amyloid within the anterior corneal stroma. Five subtypes of LCD have been identified. LCD Type I is the classic form of LCD. Symptoms include decreased vision and recurrent corneal erosions.

Granular corneal dystrophy (GCD) is a bilateral, autosomal dominant disease associated with a mutation in the *BIGH3* gene that leads to the deposition of a hyaline material in the corneal stroma. It typically presents within the first decade of life with focal granular deposits between the anterior to mid stromal regions. These opacities are discrete deposits located centrally, with clear cornea located in the periphery and clear cornea between deposits. The disease is typically asymptomatic early on, but with time the opacities can coalesce and lead to decreased vision. Recurrent corneal erosions can occur in GCD but at a lower incidence than in LCD. Three types of GCD have been described. GCD Type I is the classic form of GCD.<sup>2</sup> Avellino corneal dystrophy is GCD Type II. It is linked to a mutation in the *BIGH3* gene that leads to a deposition of both hyaline and amyloid in the corneal stroma. Typically, patients present in their second decade with granular opacities like in GCD, but later in the disease process develop lattice lines as well. The disease was thought to have originated from a family in Avellino, Italy. However, GCD type II has now been reported in patients from many other countries as well.<sup>3,4</sup>

Reis Buckler is GCD Type III. It is characterized by faint, gray-white superfi-

cial scarring patterns that are often greatest in the central cornea. The patient may experience corneal erosions, photophobia and irritation that can occur in early childhood. Analysis of the area with confocal microscopy will often reveal the absence of Bowman's layer. Vision can vary and is diminished by the severity of superficial scarring and irregular astigmatism.

Macular corneal dystrophy (MCD) is the least common, but most severe, of the stromal corneal dystrophies. Three subtypes of MCD have been described based on the presence or absence of immunoreactive keratan sulfate within various tissues. Type I does not have immunoreactive keratan sulfate in the corneal stroma, keratocytes, sera or cartilage, and is the most common variant of MCD worldwide. It is an inherited autosomal recessive condition. It is typically noted during the first decade of life, characterized by gray-white anterior stromal lesions similar to GCD. There is severe stromal haze throughout the entire stroma and limbus to limbus, with patients typically developing severe visual loss by the second to third decade of life.

Schnyder corneal crystalline dystrophy (SCCD) is a slowly progressive autosomal dominant dystrophy that appears early in life, but may not cause vision loss until the fifth decade of life. It is linked to a metabolic defect of corneal keratocytes that leads to crystalline lipid deposition. Clinically the disease presents with a ring-shaped accumulation of fine needle-shaped polychromatic crystal deposits within Bowman's layer and the anterior stroma, and is often associated with a presenile peripheral lipid arcus.<sup>1</sup>

Congenital stromal dystrophy is an autosomal dominantly inherited condition that is caused by mutations in the *DCN* (decorin) gene, leading to corneal haze and reduced visual acuity. Strabismus is common, and corneal thickness is increased.<sup>5</sup>

Corneal Fleck Dystrophy (CFD) is a rare autosomal dominant dystrophy with that is often asymptomatic. Photophobia, reduced vision and recurrent erosions may occur. It is characterized by bilateral irregular shaped "flecks" of greyish matter in the posterior stroma.<sup>6</sup> Posterior amorphous corneal dystrophy is a rare condition characterized by bilateral sheet-like opacification of the posterior stroma in association with corneal flattening and thinning. It appears to be nonprogressive and patients are asymptomatic.<sup>7</sup>

## Treatment

The treatment for the stromal corneal dystrophies would be observation and lubrication for corneal erosions if they occur. Phototherapeutic keratectomy (PTK) and corneal transplants are options as vision becomes impaired, but the dystrophy can recur in the graft.

## Pearls

Monitor visual acuity with contrast changes. While Snellen acuity might be good, loss of contrast will affect visual quality more and result in patient complaints of performance.

## Tests to help delineate structure and function

*Corneal topography*—useful for cases of stromal thinning causing irregularity involving the corneal surface.

*Anterior segment photography*—useful for documenting presence and extent of stromal changes.

*Pachymetry*—useful for documenting thickness changes or variations.

## ICD-9 Codes

- 371.53 Granular corneal dystrophy
- 371.54 Lattice corneal dystrophy
- 371.55 Macular corneal dystrophy
- 371.56 Crystalline corneal dystrophy

## References

1. [www.webeyeophth.uiowa.edu](http://www.webeyeophth.uiowa.edu), Birkholz ES, Syed NA, Wagoner MD. Corneal stromal dystrophies: A clinicopathologic review.
2. Keefe KS, Milman T, Rodrigues MM, Hidayat AA. Conjunctival and Corneal Pathology. Albert and Jakobiec's Principles and Practice of Ophthalmology, 3rd edition. Saunders. 2008: 3592-95.
3. Poulaki V, Colby K. Genetics of anterior and stromal corneal dystrophies. Seminars in Ophthalmology, 2008; 23: 1,9-17.
4. Bron AJ. Genetics of the Corneal Dystrophies: What we have learned in the past 25 years. Cornea 2000; 19(5): 699-711.
5. <http://www.ncbi.nlm.nih.gov/bookshelf/ww.dr.hs.columbia.edu/fleck>.
6. Moshegov CN, Hoe WK, Wiffen SJ, Daya SM. Posterior amorphous corneal dystrophy. A new pedigree with phenotypic variation. Ophthalmology. 1996 Mar;103(3):474-8.

## Endothelium

The endothelium is the posterior layer of the cornea, consisting of a single layer of cells, about 5µm thick, bound together and predominantly hexagonal in shape. Anteriorly it is in contact with Descemet's membrane and posteriorly with the aqueous humor. It is the structure responsible for the relative dehydration of the corneal stroma. In the normal adult eye the cell density varies from around 3000 cells/mm<sup>2</sup> in the central cornea to about 2000 cells/mm<sup>2</sup> in the periphery. With age, disease or trauma, the cell density decreases but with disease or trauma this reduction may affect corneal transparency, as some fluid then leaks into the cornea.<sup>1</sup> The endothelial corneal dystrophies, which result from primary endothelial dysfunction, include Fuchs' endothelial corneal dystrophy (FECD), posterior polymorphous corneal dystrophy (PPCD) and congenital hereditary endothelial dystrophy (CHED).

Fuchs' dystrophy (FECD) is an autosomal dominant inherited disease that affects women greater than men. It typically presents in the 5th-6th decade of life as multiple central corneal guttata (excrescences of Descemet's membrane) associated with pigment dusting on the endothelium. The condition spreads from the center toward the periphery. As the endothelial cells fall, the remaining cells enlarge to cover the gap. With the reduced number of endothelial cells, the pump function suffers.<sup>2</sup> This leads to corneal edema and loss of visual acuity. Vision is typically worse upon awakening because of the swelling induced by nighttime lid closure.<sup>3</sup> In more advanced stages, the epithelial microcysts later coalesce

and form bullae, which can rupture, causing foreign body sensation and pain, as well as exposing the cornea to the danger of infectious keratitis.

Posterior polymorphous corneal dystrophy (PPCD) is an autosomal dominant disorder with extremely variable expression. Three genes have been implicated in PPCD (VSX1, COL8A2, TCF8), but the evidence implicating VSX1 and COL8A2 is questionable. PPCD presents earlier than Fuchs' and is typically more benign. It is characterized by the early appearance of vesicle-like lesions, bands or diffuse opacities. These opacities represent more diffuse thickenings in Descemet's membrane. PPCD can result in peripheral anterior synechiae so these patients must be monitored for increased intraocular pressure. Corneal edema is also a feature of PPCD.<sup>4</sup> Congenital hereditary endothelial dystrophy (CHED) presents at or shortly after birth with bilateral corneal edema.

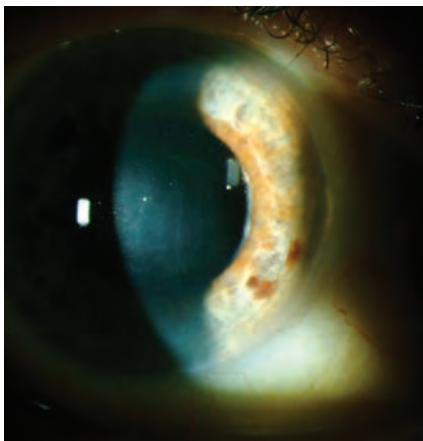
The pathology of CHED is attributed to endothelial cell degeneration during gestation.<sup>5</sup> There are two types: Type I (CHED 1) is inherited as an autosomal dominant trait that presents with clear

corneas at birth. Type II (CHED II) is more common but more severe. It is inherited as an autosomal-recessive trait, associated with nystagmus and corneal edema from birth.

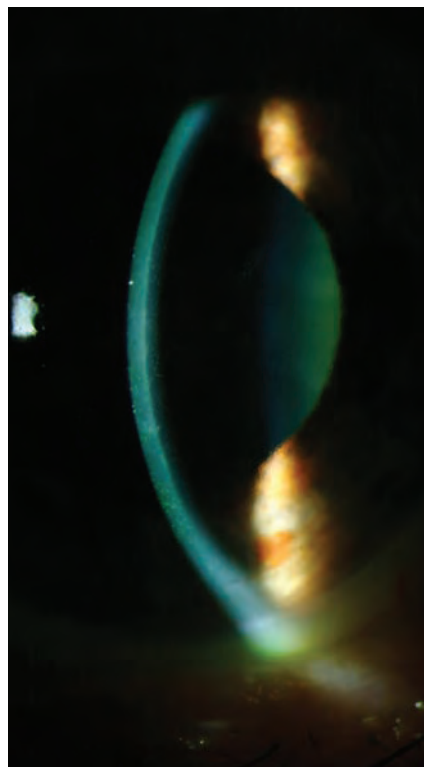
X-linked endothelial corneal dystrophy (XCED) was first described in 2006. The course in XECD is slowly progressive in the form of ground glass and moon crater-like changes of the corneal endothelium. The corneal opacification may be severe and associated with nystagmus. In advanced cases, a subepithelial band keratopathy develops.<sup>6</sup>

### Treatment

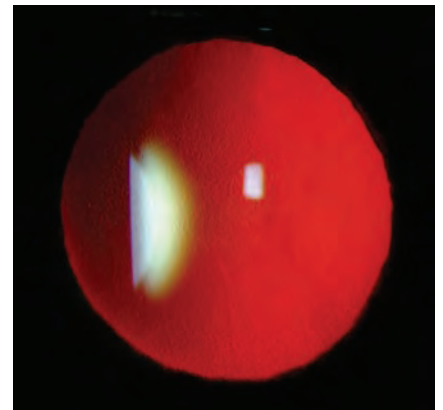
Early treatment includes hypertonic solutions during the day and nighttime hypertonic ointment. With extreme epithelial edema, bullae may form and cause pain and photophobia. Bandage



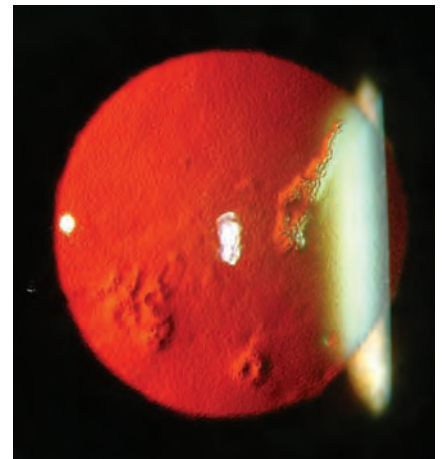
Fuchs' dystrophy with edema



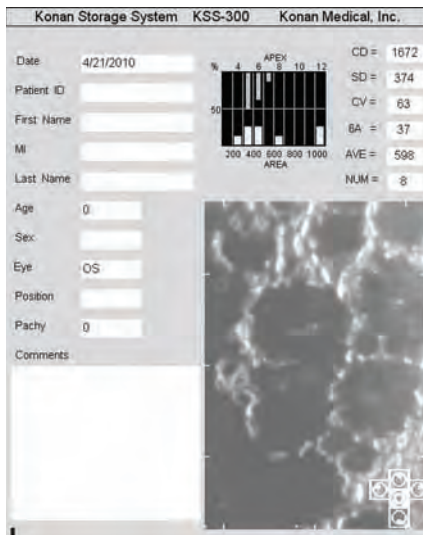
Corneal cross section of Fuchs' dystrophy with notable guttae



Fuchs' dystrophy in retro illumination



Retro illumination of Fuchs' dystrophy



Large guttae from Fuch's dystrophy shown on specular microscopy

soft contact lenses may provide temporary relief. However, these patients require careful follow-up care to reduce the risk of stromal neovascularization or infectious keratitis. If at some point vision degrades to a disabling level, surgery should be considered.

Penetrating keratoplasty had been the gold standard for treatment of complications relating to Fuchs' dystrophy and other endothelial disorders. Long term,

the results have been impressive with graft survival rates.<sup>7</sup>

Because of the complications associated with the surgery, including healing time, graft failure, and visual variability, the surgery has largely been relegated to second choice behind DSEK.

Descemet's stripping endothelial keratoplasty (DSEK) is a surgery designed to replace the endothelium alone without violating any of the overlying structures, including stroma and epithelium. The surgery has an even higher rate of success compared to PK as long as graft adhesion to the recipient cornea is successful.<sup>8</sup>

Newer techniques of reducing graft dislocation have made the surgery even safer. Graft rejection can be difficult to spot, so it is prudent to look for keratic precipitates or diffuse corneal edema.<sup>9</sup>

### Pearls

Caution should be given for use of mitomycin C for procedures in Fuchs' patients as studies have raised the potential for further damage. Monitor corneal grafts with pachymetry to look for signs of rejection. Typically, the graft will thicken over time.

### Tests to help delineate structure and function

*Anterior segment photography*—useful for documenting presence and extent of stromal thickening or other disease changes.

### Endothelial cell photos

*Pachymetry*—useful for documenting thickness changes or variations in cornea.

#### ICD-9 Codes

- 371.57 Corneal guttata / Fuch's dystrophy
- 371.58 Posterior polymorphous dystrophy

1. <http://medical-dictionary.thefreedictionary.com/corneal+endothelium> <http://emedicine.medscape.com/article/1193591-overview>.
2. DeNaeyer G. Diagnosing and Treating Corneal Dystrophy, Contact Lens Spectrum, June 2008.
3. Bass S. The genetics of corneal dystrophies. Rev Optom;143(11);2006.
4. Maumenee AE. Congenital hereditary corneal dystrophy. Am J Ophthalmol 1960; 50:1114-24.
5. Schmid E, Lisch W, Philipp W, Lechner S, Göttinger W, Schlötzer-Schrehardt U, Müller T, Utermann G, Janecke AR. A new, X-linked endothelial corneal dystrophy. Am J Ophthalmol. 2006 Mar;141(3):478-87.
6. Thompson RW, Price MO, Bowers PJ, Price FW. Long-term graft survival after penetrating keratoplasty. Ophthalmology. 2003; 110: 1396-402.
7. Terry MA, Hoar KL, Wall J, Ousley P. Histology of dislocations in endothelial keratoplasty (DSEK and DLEK): a laboratory-based, surgical solution to dislocation in 100 consecutive DSEK cases. Cornea. 2006; 25: 926-32.
8. Jordan CS, Price MO, Trespalacios R, Price FW Jr. Graft rejection episodes after Descemet stripping with endothelial keratoplasty: part one: clinical signs and symptoms. Br J Ophthalmol. 2009; 93: 387-90. Epub 2008 Nov 19.
9. Roh DS, Funderburgh JL. Impact on the corneal endothelium of mitomycin C during photorefractive keratectomy. J Refract Surg. 2009; 25: 894-7.

## Degenerations

Keratoconus and pellucid marginal degeneration are the two most common noninflammatory corneal ectasias. Though they have very distinct features, early cases of either can be difficult to distinguish from the other.<sup>1</sup>

Keratoconus is seen in adolescents and young adults. Its onset is usually at puberty. There may be a family history in 10% of patients. It may be associated with atopic disease, Down syndrome, retinitis pigmentosa, Leber's congenital amaurosis, Marfan syndrome, Ehlers-Danlos, osteogenesis imperfecta, or other noninflammatory connective tissue diseases.<sup>1</sup> Patients present with blurred vision and exhibit progressive myopia with irregular astigmatism. Slit lamp examination reveals central or paracentral corneal thinning with protrusion of the cornea at the area of thinning. Usually the apex of protrusion is just below the center of the cornea. The base of the cone is often outlined by a Fleisher ring, or an epithelial iron line. Vogt's striae are stress lines in Descemet's membrane at

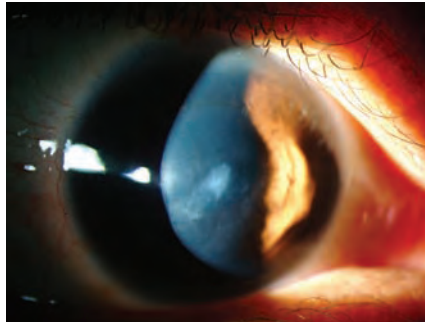
the apex of the cone that disappear with digital pressure. Breaks in Bowman's membrane can lead to scarring and subepithelial fibrosis. Acute ruptures in Descemet's membrane can lead to swelling or hydrops. Corneal topography reveals inferior steepening with paracentral thinning and elevation of the posterior and anterior corneal surfaces.<sup>2</sup>

The onset of pellucid marginal degeneration is usually similar to keratoconus, in the second through fourth decades of life.<sup>3</sup> It is also bilateral, but in contrast to keratoconus, it is not inherited and does not have other typical ocular or systemic associations. The corneal ectasia is located peripherally, usually in the inferior cornea extending from 4 to 8 o'clock positions. The thinning is typically 1 to 2 mm wide, and located 1mm to 2 mm from the limbus. Maximal corneal protrusion occurs just superior to the area of thinning, in contrast to keratoconus. The name "pellucid" means "clear." The cornea is clear without any iron rings or striae. Typically there is no scarring; however, acute hydrops can occur as

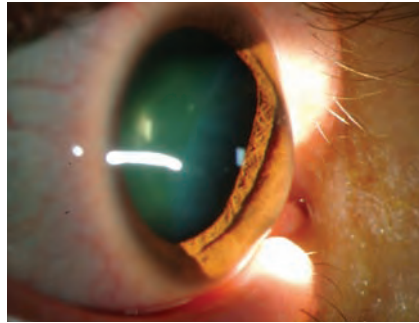
in keratoconus, which can then leave scarring. Topography reveals vertical flattening with horizontal steepening centrally, while inferiorly there is vertical steepening with horizontal flattening. This results in the classic bowed or "bent bowtie" appearance on topography.

Acute Hydrops is caused by a break in Descemet's membrane with subsequent influx of aqueous into the stroma. The break is self-repairing, with resolution over weeks to months. Hyperosmotics may hasten recovery and rarely does the cornea thin enough to perforate. A penetrating keratoplasty (PKP) may be indicated if central scarring is severe, although, frequently CL fitting is easier after a hydrops episode. PKP is contraindicated during the acute phase of the disease.

In contrast to keratoconus and pellucid marginal degeneration, Terrien's marginal degeneration usually occurs in middle age to elderly males. The thinning usually starts superiorly and may occasionally be accompanied by inflammation. Neovascular vessels may cross the area of thinning and



*Keratoconus with apical thinning, central scarring, vogts striae and Fleischers ring*



*Noticable corneal bowing in keratoconus*

#### ICD-9 Codes

- 371.60 keratoconus unspecified
- 371.61 keratoconus stable
- 371.62 keratoconus acute hydrops
- 371.00 corneal scar unspecified
- 367.22 irregular astigmatism
- 371.48 Terriens marginal degeneration
- 371.10 Iron deposits cornea

topography is not keratoconus and diagnosis should not be made solely on an axial topographical map. Comprehensive diagnosis, treatment, topography interpretation and fitting videos are available at [www.GPLI.org](http://www.GPLI.org).

#### References

1. Cornea, second edition volume 1, Krachmer, Mannis and Holland editors, Elsevier 2005 pages 955-74.
2. J Refract Surg. 2009 Oct;25(10 Suppl):S958-62. Keratoconus detection using corneal topography. Holladay JT.
3. Joseph A, Fernandez ST, Ittyarath TP, Williams J. Keratectomy in terriens marginal degeneration. Indian J Ophthalmol 1984;32:113-4.

there may be corneal lipid deposition.

#### Treatment

Treatment options for Keratoconus include collagen crosslinking, INTACTS, full thickness penetrating keratoplasty or deep anterior

lamellar keratoplasty, and contact lenses.

#### Pearls

Keratoconus should be considered anytime visual acuity does not meet expected norms and other pathology is not obvious. All inferior steepening seen on corneal

## Mechanical

### ABRASION

Corneal abrasions are a common form of injury resulting from ocular trauma. When the cornea is injured or damaged, sight-threatening consequences are always a possibility especially in the contact-lens wearing patient. Contact lenses can compromise the corneal epithelium and may facilitate the development of infectious or non-infectious keratitis. It is important to recognize the signs and symptoms of corneal abrasion in order to ease the patient's pain and provide proper medical management to hasten visual recovery.

#### Etiology

Damage to the corneal epithelium results in loss of the connections of the surrounding epithelial cells, but Bowman's layer generally remains intact. Deeper involvement affecting stroma is rare and generally due to traumas from a sharp or abrasive object. Often, corneal flaps of various sizes and thickness can be seen.<sup>1</sup> The speed by which the abrasion resolves can be affected by a variety of factors including whether the patient has diabetes, corneal denervation, dry eye, lagophthalmus, previous recurrent corneal erosions or basement membrane changes. In general, an epithelial insult will recover within 24-48 hours and is accomplished by having the neighboring epithelial cells slide over and begin covering the wound. Common causes of mechanical abrasions are fingernail, paper, foreign body, curling iron, mascara brush, plant or other vegetative source and contact lens.<sup>1</sup>

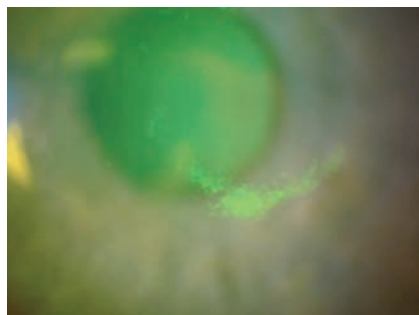
### Presentation

Slit-lamp biomicroscopy of the injured cornea reveals epithelial disruption and diffuse corneal edema. In severe cases, when edema is excessive, folds in Descemet's membrane may be visible. The corneal abrasion should be documented for location, size, shape and depth with either a drawing or photograph, making any notation of infiltrative process. This visual documentation will aid in follow-up to chart the healing progress. Fluorescein dye can be instilled to identify the corneal defect. The newly created wound appears bright green compared to the rest of the cornea because the dye accumulates in the defect.<sup>1,2</sup> The anterior chamber should be observed and any anterior chamber reaction should be noted.

Patient symptoms include eye pain, foreign-body sensation, photophobia, blepharospasm and tearing. The time, place and activity surrounding the injury should be noted. For medical and legal purposes, the visual acuity (VA) should be taken before performing any procedures. Differentials include recurrent corneal erosion, herpes simplex keratitis, and confluent superficial punctate keratopathy.<sup>2</sup>

#### Treatment

There are several treatment options for corneal abrasions, including bandage soft contact lenses, topical antibiotic ointment and drops, topical non-steroidal and steroidal anti-inflammatory drops, cycloplegic preparations and hypertonic drops and ointments. Topical antibiotics are the mainstay of corneal abrasion therapy. There is a risk of infection with any open wound or defect involving the basal lamina. Topical antibiotics such as polymyxin B/trimethoprim, aminoglycosides or fluoroquinolones are all reasonable for providing prophylactic antibiotic coverage.<sup>3</sup> Depending on the extent and severity of presentation, dosing might be more aggressive at q2h for 24 hours or more conservative at q.i.d. Antibiotic ointments can be liberally applied during the day or augment drops by using them at bedtime.<sup>2</sup> Ointments tend to provide better barrier and lubricating function, but will temporarily blur vision. Debridement of loose or hanging epithelium is necessary to enhance healing.<sup>1,2</sup> Therapeutic soft contact lenses can be used in abrasion



*Corneal abrasion from fingernail*

management. Large abrasions have been found to heal more quickly under the protection of a bandage contact lens.<sup>3,5</sup> The use of bandage contact lenses, however, does not come without risk, including ocular irritation, epithelial and stromal edema, sterile infiltrates and hypopyon, microbial infection and ulceration.<sup>4</sup> Bandage contact lenses should be avoided in ALL situations where plant injury or false fingernails is suspected because of the risk of fungal keratitis.<sup>5</sup>

Bed rest, inactivity and over-the-counter analgesics can be used to manage pain.<sup>6</sup> Topical non-steroidal anti-inflammatory drops can be a useful adjunctive therapy for the management of pain from corneal abrasion and often obviate the need for oral pain medications. These medications provide patient comfort and do not adversely affect corneal healing time.<sup>6</sup> Oral analgesics may be necessary for pain not controlled by topical medications. These include aspirin, ibuprofen, toradol and tramadol. These medications provide both analgesic as well as anti-inflammatory effects. Analgesics such as acetaminophen lack the anti-inflammatory component. The above anti-inflammatory medications can be prescribed in combination with narcotic analgesics such as codeine or hydrocodone. Cycloplegic agents should be prescribed to paralyze the ciliary body and thus decrease ocular pain. Mild abrasion cases can be managed with cyclopentolate 1 percent,<sup>4</sup> while more severe presentations may require scopolamine 0.25% or homatropine 2% or 5%.<sup>5,6</sup>

Fortunately, the cornea heals very rapidly, but keep in mind that recurrent corneal erosion is possible even months to years later.<sup>1,6</sup> Lesions that are purely epithelial often heal quickly and completely without scarring. The presence of subepithelial infiltration may be a

sign of infection. Lesions such as these should be considered vision-threatening and may warrant culturing and the use of fortified antibiotic therapy.<sup>2</sup> To prevent recurrent erosion and reduce corneal edema, a hypertonic solution or ointment may be prescribed along with the other medications after the cornea has re-epithelialized.<sup>2</sup>

### Recommendations

If the patient's blepharospasm is intense and visual acuity cannot be obtained, instill one drop of anesthetic onto the bulbar conjunctiva. This should allow you to immediately record visual acuity. A new (sterile) bottle of anesthetic should be used if a penetrating injury is suspected.

Always remember to evert the upper lid to check for residual foreign substance. Cycloplegics will make the patient more comfortable and decrease the likelihood of traumatic iritis developing. Steroids are NOT always necessary and should be avoided initially.<sup>2</sup>

If using a bandage lens, make sure that you are using a lens of appropriate Dk/t to reduce the likelihood of corneal swelling.

Avoid bandage lenses if injury involves plant material or false fingernails.<sup>1,2</sup>

Patching is rarely necessary. Never patch contact lens related abrasions or injuries involving vegetative material or false fingernails. Patients should be re-evaluated within 24 hours.<sup>2</sup>

Encourage the use of nighttime hyperosmotic ointments up to three-six months post insult in cases involving a significant abrasion.

### References

1. Arunagiri G, Trikha R. Corneal Abrasions, Contusions, Lacerations, and Perforations. IN: Roy FH, Fraunfelder FW and Fraunfelder FT: Current Ocular Therapy. Saunders/Elsevier, New York, 2008, pp. 359-62.
2. Cullom RD, Chang B. Trauma: Corneal Abrasion. In:

Cullom RD, Chang B eds. The Wills Eye Manual: Office and Emergency Room Diagnosis and Treatment of Eye Disease. Philadelphia, PA: JB Lippincott, 1994: 22-3.

3. Gurwood AG. Managing corneal abrasions. www.optometry.co.uk.

4. Webster RG. Corneal Injuries. In: Smollen G, Thoft RA. The Cornea. Boston: Little, Brown & Co. 1987: 517-27.

5. Fujikawa LS, Nusenblatt RB. Recurrent and chronic corneal epithelial defects. In: Abbott RL, ed. Surgical Intervention in Corneal and External Diseases. New York, NY: Grune & Stratton. 1987: 59-67.

6. Sowka J, Gurwood A, Kabat A. Handbook of Ocular Disease Management. Rev Optom.

### ICD-9 Codes

- 364.01 Iritis, acute
- 918.1 Corneal abrasion
- 918.2 Conjunctival abrasion
- 930.1 Corneal foreign body.

### EXPOSURE KERATOPATHY

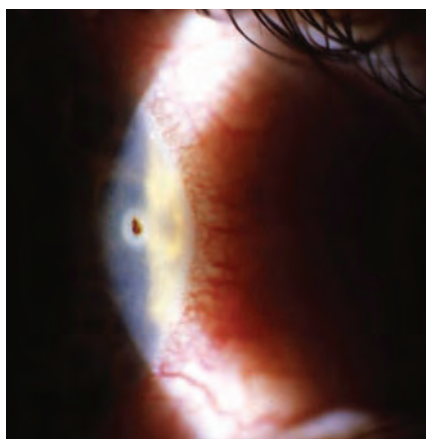
Exposure staining of the ocular surface appears to be associated with incomplete blinking and can have several different causes.<sup>1,2</sup> Whenever possible, correcting any underlying problem will often provide immediate relief and prevention is critical in many cases to maintain normal corneal clarity.<sup>2</sup>

### Etiology

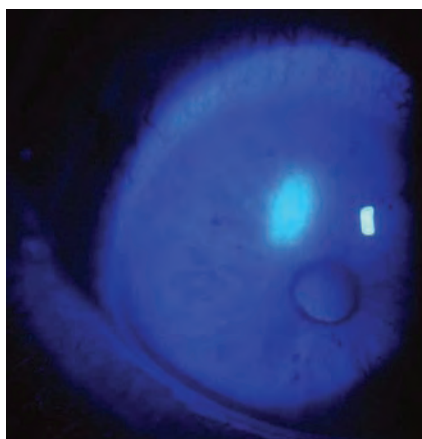
Major causes of exposure keratopathy relate to lid malposition or deformity (eyelid scarring from trauma or herpes zoster), ectropion, or chemical burns.<sup>1,2</sup> Other causes stem from lid surgery (especially ptosis repair and blepharoplasty), nocturnal lagophthalmos, sedation and altered mental status, proptosis or cranial nerve palsies that affect the lid or eye.<sup>2</sup>

### Treatment

A careful medical history may uncover previous Bell's palsy, lid surgery, anterior segment trauma or thyroid disease.<sup>2</sup> Careful evaluation should include assessment of eyelid closure/laxity and corneal exposure. Always check to be certain there is no evidence of reduced corneal sensation increasing the risk of corneal complications.<sup>2</sup> A slit lamp examination will often uncover any tear film abnormalities, corneal integrity issues or other external or anterior chamber reaction.<sup>2</sup> Lubrication is essential for any sedated or obtunded patient.<sup>2</sup> Artificial tears, lubricating ointments and gels are the mainstay of treatment. Punctal plugs can also be used when necessary. Eyelid taping and patching can be tried when the condition is believed to be temporary. In severe, recalcitrant cases, with progressive corneal deterioration, eyelid reconstruction, partial tarsorrhaphy and amniotic membrane transplants can be beneficial.<sup>2</sup> Orbital decompression for proptosis and eyelid gold weights for seventh nerve palsies can be helpful.<sup>2</sup>



Corneal foreign body



Corneal abrasion

## Recommendations

Close observation is necessary when an infection is present or a high probability for infection exists.

Floppy eyelid syndrome and Parkinson's disease can also cause a poor blink and result in exposure staining.<sup>2</sup>

Vaseline petroleum jelly preparations applied to the periocular skin can be therapeutic in certain cases of ectropion and may obviate the need for surgery.

## References

- McMonnies C: Incomplete blinking: exposure keratopathy, lid wiper epitheliopathy, dry eye, refractive surgery and dry contact lenses. *Contact Lens and Anterior Eye*, 30(1), 37-51.
- Ehlers JP and Shah CP. Exposure Keratopathy. In: Ehlers JP and Shah CP eds. *The Wills Eye Manual: Office and Emergency Room Diagnosis and Treatment of Eye Disease*. Philadelphia, PA: Wolters/Kluwer/JB Lippincott, 2008: 55-6.

## FOREIGN BODY

A variety of materials in the environment resulting in foreign body of the eye can be found on the surface of the cornea or conjunctiva, or even be intraocular/intraorbital.<sup>1,2</sup> Fortunately, the majority of foreign bodies encountered in clinical practice lodge on either the cornea or conjunctiva and do not enter the eye or orbit. A dilated eye examination must be performed to rule out any posterior segment involvement and appropriate testing such as a B-scan ultrasonography, computed tomography (CT scan) of the orbit or ultrasonographic biomicroscopy (UBM) to rule out an intraocular or intraorbital foreign body should also be done.<sup>1</sup>

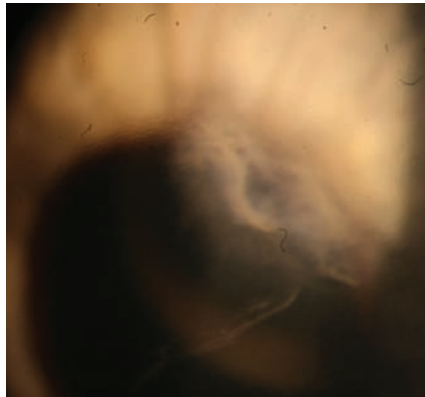
### ICD-9 Codes

- 370.34 exposure keratoconjunctivitis
- 351.0 Bell's palsy

## Presentation

Patients will generally provide a history of trauma and foreign body sensation with any foreign body of the cornea and/or

conjunctiva. Additional symptoms include photophobia and lacrimation. A slit lamp examination will reveal a single or multiple foreign body. Metallic corneal foreign body will produce rust. The eye is injected with eyelid edema and punctate keratopathy is seen with a foreign body under the lid. An anterior chamber reaction is possible with any significant involvement.<sup>1</sup>



Corneal laceration

## Treatment

A careful history will determine the mechanism of injury. Some attempt should be made to determine the size, shape weight, velocity, force and composition of the object.<sup>1</sup> Visual acuity assessment should be performed before any procedure is attempted. Topical anesthetic agents can control pain and blepharospasm.<sup>1</sup>

Slit lamp examination will determine the location, depth and whether there are any self-sealing lacerations. Evert the eyelids and inspect carefully the fornices. With conjunctival laceration be certain Tenon's membrane is intact to rule out scleral laceration or perforation of the globe.<sup>1</sup>

Corneal foreign body can be removed by use of a fine forceps or foreign body spud at the slit lamp after topical anes-

thetic is applied to the eye. Multiple superficial foreign bodies may be irrigated.<sup>1</sup> Broad spectrum topical antibiotics should be used to treat the resultant defect after assessing the size of the defect<sup>1</sup> (see "Corneal Abrasion" section for a more complete discussion). Similar treatment employed for any epithelial defect or abrasion can be used for pain management. Conjunctival foreign body can usually be removed successfully using a cotton-tipped applicator soaked in topical anesthetic or fine forceps.<sup>1</sup> Residual and not easily accessible conjunctival foreign bodies may sometimes be left without undue harm unless they are infectious or pro-inflammatory.<sup>1</sup>

## Recommendations

Carefully examine the anterior chamber and iris for any signs of intraocular foreign body. A low intraocular pressure or anterior chamber shallowing effects may indicate corneal penetration.<sup>1</sup>

Any infiltrate suggesting an infectious process must be managed with appropriate antibiotic therapy.<sup>1</sup>

Remove any rust as completely as possible. This might require allowing time for the rust to migrate to the surface of the cornea with removal of the rust after several days in order to minimize scarring.<sup>1</sup>

### ICD-9 Codes

- 930.0 corneal foreign body
- 930.1 foreign body in the conjunctival sac
- 930.8 foreign body in other and combined sites on external eye

## References

- Ehlers JP and Shah CP. Corneal and Conjunctival Foreign Bodies. In: Ehlers JP and Shah CP, eds. *The Wills Eye Manual: Office and Emergency Room Diagnosis and Treatment of Eye Disease*. Philadelphia: Wolters/Kluwer/JB Lippincott, 2008: 16-18.
- Onofrey B: Superficial ocular foreign body. In: Onofrey BE, Skorin L and Holdeman NR eds. *Ocular Therapeutics Handbook*. Lippincott-Raven, Philadelphia 1998: 303-4.

## Chemical

### Toxic/Solution Keratitis

Chemical toxicity can result from any contact lens solution, and care products are an under-recognized cause of intolerance to contact lens wear. A wide range of signs and symptoms are possible ranging from mild sensitivity from a micro-punctate keratopathy to significant discomfort as a result of diffuse corneal staining. The patient may experience a foreign body

sensation and photophobia. The condition is generally bilateral and disappears after removing the offending agent.

### Etiology

Virtually any contact lens care product has the potential to create a toxic effect to the ocular surface, especially inadvertent application of non-neutralized hydrogen peroxide directly in the eye. A

less severe adverse ocular response of diffuse punctate staining and conjunctival redness has been associated with wearing silicone hydrogel lenses when using certain multipurpose disinfecting solutions.<sup>1</sup>

### Presentation

Patients experiencing a toxic response will often present with symptoms of stinging, tearing, burning, dryness and



a decreased wearing time. Signs include redness, conjunctival chemosis, follicular response, variable corneal staining patterns and infiltrates.

### Treatment

Palliative therapy should include the use of artificial tears (non-preserved) or gels/ointments and antibiotic prophylaxis when indicated for more severe forms of coalesced corneal staining. Topical corticosteroids or antibiotic/steroid combinations may be warranted especially when there is an infiltrative response assuming the risk of corneal infection has been carefully considered and ruled out. A change in solution used is advised to remove the offending agent and some clinicians will switch from a multipurpose solution to an oxidative system.

### Recommendations

Some mild forms of toxicity are barely detectable and the use of vital stain is essential in evaluating patients who are symptomatic with lens wear.

Eyes that experience solution toxicity are more likely to experience a corneal infiltrative event.<sup>1</sup>

#### ICD-9 Codes

- 370.21 Punctate keratitis
- 370.3 Certain types of keratoconjunctivitis
- 370.4 Other and unspecified keratoconjunctivitis

#### References

1. Carnt N, Jalbert J, Stretton S et al: Solution toxicity in soft contact lens daily wear associated with corneal inflammation. *Optometry and Vision Science*; April 2007 84 (4): 309-315.

### CHEMICAL BURNS

Chemical injuries have the potential to permanently damage the ocular surface (unilateral or bilateral). Pathophysiological cascades that may influence the final visual outcome include: 1) ocular surface injury and repair, 2) stromal matrix repair and or ulceration and 3) corneal inflammation.<sup>1,2</sup> Ocular burn severity correlates to exposure duration and noxious agent.<sup>4</sup> Specifically, chemical burn severity relates to pH, duration, solution quantity and permeability.<sup>3</sup> Ocular burns caused by acids are generally less severe compared to alkali burns due to the natural buffering capacity of the corneal stroma and the barrier to penetration formed by coagulated epithelial cells.<sup>1</sup> Immediate therapy should include prompt irrigation and removal of any remaining reservoir

of chemical contact.<sup>2,3</sup> Ocular burns represent 7%-18% of ocular trauma. The vast majority are chemical burns that occur in the industrial/occupational setting.<sup>4</sup>

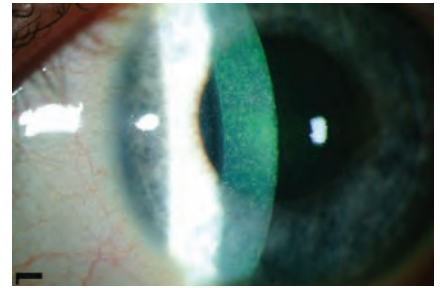
### Etiology

Any noxious agent or radiant energy (thermal or ultraviolet) has potential to irritate/injure the ocular surface and produce other more severe forms of anterior segment abnormality. This includes alkali (i.e. lye, cements, plasters, airbag powder), acids, solvents, detergents, and irritants (i.e. mace).<sup>3</sup> Burns damage tissues primarily by denaturing and coagulating cellular proteins and through vascular ischemic changes.<sup>1,4</sup>

- Thermal burns: Injury from radiant energy results from contact with hot liquids, gases or molten metal. Cell death from thermal burns is generally limited to the superficial epithelium, but thermal necrosis and deeper penetration can occur.<sup>4</sup>
  - Ultraviolet burns: Punctate keratitis results from an epithelial injury. Delayed pain is secondary to actinic keratosis.<sup>3</sup>
  - Alkali burns: Since alkali substances are more lipophilic, they penetrate more rapidly than acids.<sup>1,3</sup> The damaged tissues stimulate an inflammatory response that damages the tissue further by release of proteolytic enzymes (liquefactive necrosis) and alkali substances can pass into the anterior chamber rapidly exposing the crystalline lens, ciliary body, and trabecular meshwork.<sup>3,4</sup> When the pH value is above 11.5, irreversible damage occurs.<sup>4</sup>
- Acid burns: Acid burns cause protein coagulation of the epithelium, thereby limiting in most cases further penetration and limiting progression beyond the superficial cornea.<sup>4</sup>

### Presentation

Patients will often give a history of a liquid or gas being splashed or sprayed into the eye or of particles falling into the eye.<sup>4</sup> The local Poison Control Center may be an invaluable resource in determining the nature of the chemical when unknown.<sup>3</sup> Common complaints include: pain, foreign body sensation, blurred vision, excessive tearing and photophobia.<sup>2,4</sup> A wide

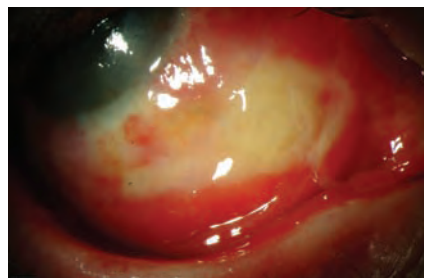


Chemical toxicity secondary to multiple topical antimicrobial medications

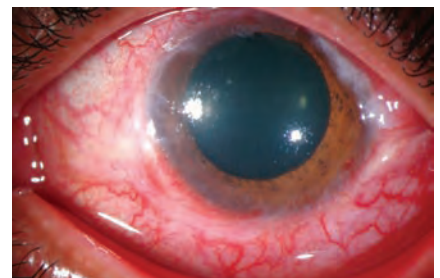range of findings will be influenced by the severity of the injury but may include particles in the fornix, conjunctival inflammation, perilimbal/limbal ischemia, corneal epithelial defects, stromal haze, anterior chamber reaction, adnexal damage/scarring, increased intraocular pressure, periocular skin burns and corneal perforation/melt.<sup>3,4</sup> Severe burns may also cause a pronounced chemosis, conjunctival blanching and local necrotic retinopathy resulting from direct penetration of alkali through the sclera.<sup>2,3</sup>

### Treatment

The initial physical examination should assess of potential life threatening injuries. Initial examination of the eye may be limited to pH values and acuity determination.<sup>2,3</sup> After copious irrigation for 20-30 minutes with saline or water, a full ocular examination is essential.<sup>3</sup> Fluorescein and pH evaluation is necessary after a short equilibration period. Ocular irrigation with lactated Ringer's solution or other available intravenous solutions should be continued in the emergency facility. Attention should be given to the clarity of the cornea, degree of limbal ischemia, and intraocular pressure. Lid eversion is important to detect and eliminate any particles or foreign bodies. Immediately following the injury, it is important to estimate and grade the severity of limbal stem cell injury and debride any necrotic epithelium to allow normal tissue to re-epithelialize.<sup>1</sup> The grading can be accomplished by assessing the degree of limbal, conjunctival, and scleral ischemia and



Conjunctival alkali burn



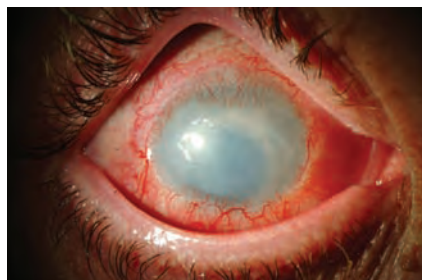
Acid burn with sloughed epithelium

necrosis, and by evaluating the penetration of the noxious agent by assessing the clarity of the stroma and any additional anterior segment abnormalities.<sup>1,2</sup> If the limbus is affected significantly, the cornea may develop epithelial defects and conjunctival invasion onto the cornea.<sup>3</sup>

Depending on severity, therapeutic agents include antibiotic for significant epithelial defects, cycloplegia, topical steroids and anti-glaucoma agents when IOP is elevated.<sup>2,4</sup> Using steroids beyond seven days after severe burns is controversial and will occasionally result in perforation and ulceration of the cornea due to the effects on wound repair.<sup>1</sup> Topical artificial tears and lubricating ointments play a significant role in managing these cases. Other cases may require lysis of conjunctival adhesions,

#### ICD-9 Codes

- 370.24 photo keratitis
- 940.1 chemical burn of the eyelid and periocular area
- 940.2 alkaline chemical burn of cornea and conjunctival sac
- 940.3 acid chemical burn of cornea and conjunctival sac
- 940.4 other burn of cornea and conjunctival sac
- 940.5 burn with resulting rupture and destruction of eyeball

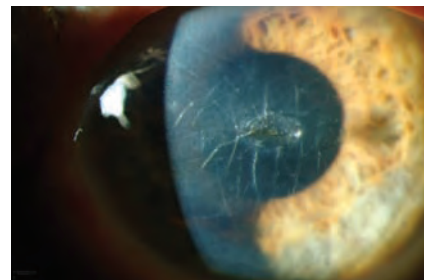


Alkali burn four months after injury

bandage contact lenses, aprotinin (inhibits proteinase activity), topical heparin (re-opening of occluded blood vessels, ascorbate and citrate for alkali burns).<sup>1</sup> With any melting processes of the cornea, collagenase inhibitors, such as tetracycline, and tissue adhesives may be used.<sup>3</sup> Glaucoma following chemical burns will generally respond to conventional agents (oral and topical). Additionally, emergent patch grafts may be necessary. Added measures such as conjunctival or limbal stem cell transplants from the fellow eye may be necessary for injuries that fail to heal within several weeks to months.<sup>3,4</sup>

#### Recommendations

If an epithelial defect is not appreciated initially, re-instill fluorescein; the defect may be slow to take-up dye. If the entire



Severe corneal edema requiring PKP six years after alkali burn

epithelium has sloughed, Bowman's layer remains and takes up fluorescein poorly.<sup>3</sup>

Closely monitor IOP. An immediate rise in pressure can result from collagen deformation and shortening that directly affects the anterior chamber. Prolonged increases in IOP are directly related to the degree of anterior chamber inflammation.<sup>4</sup>

#### References

1. Wagoner MD: Chemical injuries of the eye: current concepts in pathophysiology and therapy. *Surv Ophthalmol.* 1997; 41(4): 275-279.
2. Roy FH: Alkaline Injury. IN: Roy FH, Fraunfelder FW and Fraunfelder FT: *Current Ocular Therapy.* Saunders/Elsevier, New York, 2008, pp. 277-78.
3. Ehlers JP and Shah CP. Chemical Burn. In: Ehlers JP and Shah CP eds. *The Wills Eye Manual: Office and Emergency Room Diagnosis and Treatment of Eye Disease.* Philadelphia, PA: Wolters/Kluwer/JB Lippincott, 2008: 12-15.
4. <http://emedicine.medscape.com/article/798696-overview>.

## Inflammatory Corneal Conditions

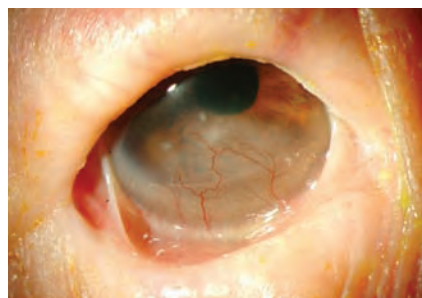
### STAPH MARGINAL KERATITIS/CLPU Etiology

A contact lens-induced peripheral ulcer (CLPU) typically presents as a single well-circumscribed, circular, dense focal corneal infiltrate involving the anterior corneal layers.<sup>1</sup> Compared to the much more feared and complicated microbial keratitis, it is sometimes difficult to distinguish between a CLPU and microbial keratitis, so microbial keratitis is always considered part of the differential diagnosis. Differentiating a contact lens-induced peripheral ulcer (CLPU) from early stage microbial keratitis (MK) is primarily based on clinical judgment rather than on microbiologic or histopathologic investigations.<sup>2</sup> However, there is often an overlap in the signs and symptoms that can complicate the diagnosis. A critical sign, however, is the response of the presentation immediately after lens wear is discontinued.<sup>3</sup> CLPUs are different from peripheral marginal ulcers caused by *S. aureus* exotoxins that are often found in the corneal periphery, which are more

often oval, and may be associated with corneal vascularization.

#### Presentation

Patients may complain of redness, discomfort, light sensitivity, tearing and foreign body sensation. These symptoms are milder than in microbial keratitis; however, suspicion must always be high in contact lens-wearing patients of a possible underlying microbial cause. Slit-lamp examination will demonstrate mild

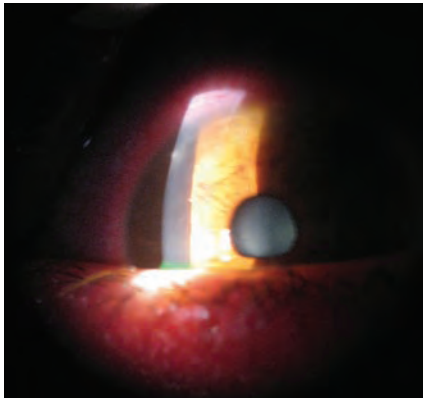


Pemphigoid

to moderate conjunctival injection near the corneal infiltrate and a round, focal peripheral infiltrate approximately 2mm or less. The overlying small epithelial defect stains with fluorescein. Anterior chamber reaction, if present, is very mild. A significant anterior chamber reaction raises the suspicion of microbial keratitis.

#### Treatment

The initial management of CLPU involves discontinuing contact lens wear. Patients are often started on topical antibiotics such as a fourth-generation fluoroquinolone and followed with serial examinations for evidence of either improvement or worsening of the condition to rule out microbial keratitis. Topical steroids should generally be withheld until the epithelial defect is healed and there is no evidence of fungal, protozoan, or herpetic infection. In staph-induced marginal keratitis where severe inflammation exists, antibiotic and corticosteroid combination drops or ointments can be rubbed into the lid margins following lid scrubs.



Contact lens acute red eye with peripheral infiltrate

Oral therapy with tetracycline 250mg four times a day or doxycycline 100mg twice a day or minocycline 50mg twice a day may be needed for more severe infections. The lesion generally heals with a small, mid-stromal scar and recurrence is not uncommon.

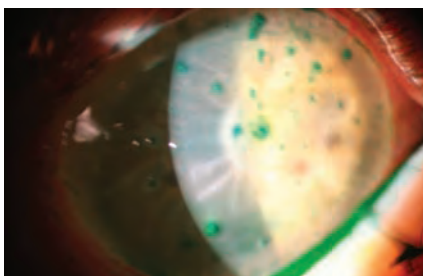
#### ICD-9 Codes

- 370.00 Corneal ulcer, unspecified
- 370.01 Marginal corneal ulcer

## DRY EYE

### Etiology

From the 2007 DEWS Report: "Dry eye is a multifactorial disease of the tears and ocular surface that results in symptoms of discomfort, visual disturbance, and tear film instability with potential damage to the ocular surface. It is accompanied by increased osmolarity of the tear film and inflammation of the ocular surface."<sup>4</sup> It is a common disorder that especially affects adults and women and can cause quality of life impairment comparable to migraine, shortness of breath and chronic renal insufficiency, depending on its symptoms or complications.<sup>5</sup> There are two etiopathogenic distinctions of dry eye: aqueous deficient and evaporative. There are numerous causes for each. Dry eye is the single most common complaint among contact lens wearers. It



Filamentary keratitis and culture positive fungal ulcer in Sjogren's syndrome

is the number one reason patients discontinue contact wear. Approximately 34% of patients discontinue contact lens wear at least once, most frequently because of dry eye symptoms.

### Presentation

Physical examination includes visual acuity measurement, external examination, and slit-lamp biomicroscopy.<sup>6</sup> Additional diagnostic tests may be performed to assess tear film instability, ocular surface damage, and aqueous tear flow. Tear film instability is commonly evaluated by performing a tear film break-up time test. Ocular surface damage is commonly assessed by staining with rose bengal, lissamine green, or fluorescein dye. Abnormal corneal and/or conjunctival staining patterns, observed on slit-lamp examination, are a sign of damage. Aqueous tear flow is commonly assessed by performing a Schirmer test. While helpful in making the diagnosis, diagnostic test results generally correlate poorly with symptoms.<sup>7</sup>

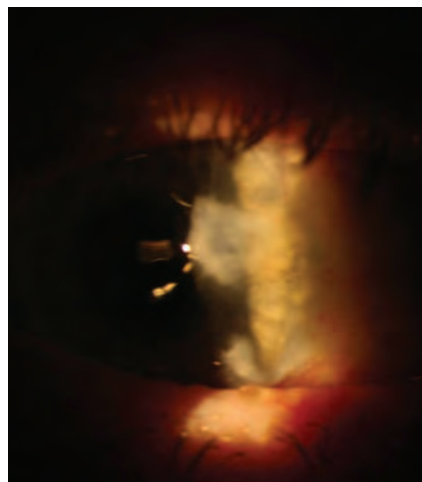
### Treatment

There is no single method for determining if a patient is a candidate for

dry eye therapy. Patient symptoms and clinical signs should be considered when deciding on therapeutic intervention. The management of dry eye disease (DED) encompasses both pharmacologic and non-pharmacologic approaches, including avoidance of exacerbating factors, eyelid hygiene, tear supplementation, tear retention, tear stimulation, and anti-inflammatory agents.<sup>8</sup> Artificial tears are the mainstay of DED therapy but, although they improve symptoms and objective findings, they do not resolve the underlying inflammation in DED. Topical corticosteroids are effective anti-inflammatory agents, but are only used short-term because of their adverse-effect profiles. Topical cyclosporine—currently the only approved pharmacologic treatment for DED—is safe for long-term use and is a disease-modifying therapy. Treatment selection is guided primarily by DED severity.<sup>9</sup> Replacement of tear volume with nonpreserved wetting agents and standard typical anti-inflammatory corticosteroid and/or cyclosporine A continues to be central current conventional therapy for dry eye.<sup>10</sup> Autologous serum eye drops have been reported to be effective for the treatment of severe dry eye-related ocular surface disorders (Sjogren's syndrome).<sup>11</sup>

#### ICD-9 Codes

- 370.33 Keratoconjunctivitis sicca, not Sjogren's
- 370.23 Filamentary keratitis



Salzmann's nodular degeneration

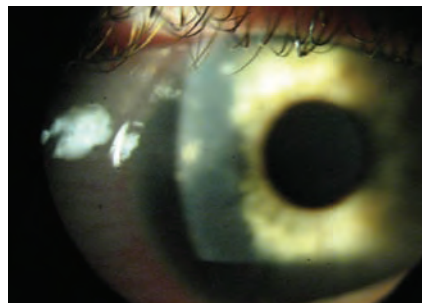
## UVEITIS

### Etiology

Anterior uveitis is an important condition in primary eye care. It is the most common form of uveitis encountered in general ophthalmic with acute anterior uveitis (AAU) occurring significantly more often than chronic anterior uveitis (CAU) or posterior uveitis.<sup>12</sup>

### Presentation

Symptoms of unilateral pain, photophobia, redness and watering develop over one to two days, with little or no effect on vision.<sup>13</sup> Pain and photophobia may precede slit lamp signs, due to unseen ciliary body inflammation. Signs depend on the severity of the inflammation but typically include circum-limbal flush, miotic pupil, anterior chamber cells and flare, and small, fine keratic precipitates (KP). The pupil may appear sluggish and may be small and irregular. In more severe attacks, posterior synechiae, peripheral anterior synechiae, corneal edema, spill-over vitritis and macular



Peripheral corneal ulcer

edema may be seen. The intraocular pressure (IOP) generally falls slightly with attacks but occasionally it may increase.<sup>14</sup>

### Treatment

In the majority of cases of AAU, especially those of mild to moderate intensity, topically applied steroids are the mainstay of treatment.<sup>15</sup> Dosage regimens for topically applied steroids depend on the severity of AAU but all strategies must include aggressive initial treatment with the goal of bringing the inflammation under control quickly. Hourly instillation for the first few days is typical. A loading dose to achieve a therapeutic concentration at an early stage is often recommended.<sup>16</sup> Mydriatic/cyclopegic agents may also be added to reduce pain and prevent the development of posterior synechiae.

#### ICD-9 Codes

- 364.00 Acute and subacute iridocyclitis, unspecified
- 364.01 Primary iridocyclitis
- 364.02 Recurrent iridocyclitis
- 364.05 Hypopyon

## CONTACT LENS SUPERIOR LIMBIC KERATOCONJUNCTIVITIS

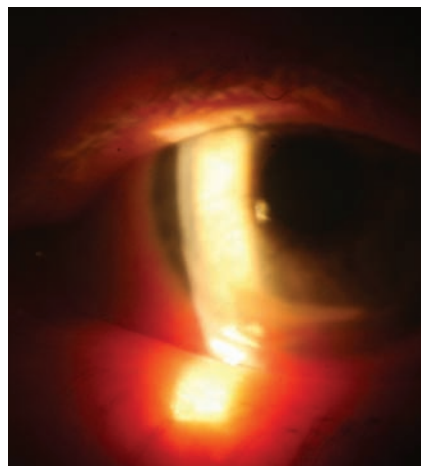
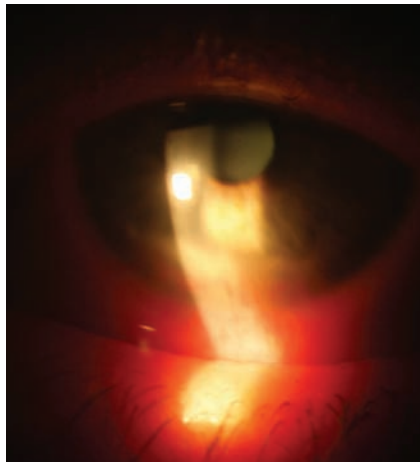
### Etiology

CLSLK and SLK are inflammatory conditions that affect the superior bulbar conjunctiva and adjacent corneal surface. Contact Lens Superior Limbic Keratoconjunctivitis (CLSLK) is recognized as a completely separate event from Theodore's Superior Limbic Keratoconjunctivitis (SLK). CLSLK is identified in patients wearing soft lenses by superior corneal staining combined with tarsal and superior limbal hypertrophy. There may be an association with atopy, contact lens-related trauma, hypoxia, hypersensitivity responses to proteins deposited on contact lenses and chemical preservatives, especially thimerosal in lens care systems. SLK on the other hand is seen in older populations of women and might be related to thyroid eye conditions or other autoimmune diseases.

### Presentation

Both conditions will manifest with punctate staining of the superior corneal epithelium, although CLSLK is often a more aggressive presentation. SLK is typically a bilateral condition and is clearly evident upon visualization. CLSLK is usually monocular with tremendous variability of presentation. Patients with CLSLK may complain of contact lens intolerance, light sensitivity, burning, redness, watering and pain. Upon lifting the upper lid, an intense area of local-

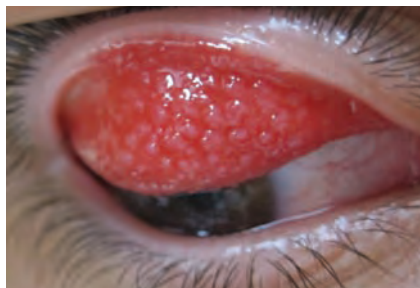ized injection at 12 o'clock with associated loose and boggy bulbar conjunctiva can be observed. An irregular epithelial surface, punctate staining with fluorescein, and



*Staph marginal ulcer*

#### ICD-9 Codes

- 370.21 Punctate keratitis
- 371.82 Corneal disorder due to contact lens
- 372.10 Chronic conjunctivitis, unspecified.



*Giant papillary conjunctivitis*

subepithelial infiltrates may be found on the superior aspect of the cornea in association with hyperemia of the superior bulbar conjunctivae. There may be significant neovascularization and fibro-vascular pannus extending into the superior cornea. Evert the eyelids on all contact lens patients, paying careful attention to the bulbar and tarsal conjunctivas at the superior limbus.

### Treatment

Case management for CLSLK is straightforward. Discontinuation of contact lens wear and treatment with frequent preservative-free ocular lubricants is the initial therapy. In most cases, this palliative treatment will suffice. In more severe presentations where the patient is experiencing significant discomfort, it might be necessary to concurrently treat the patient with steroid drops during the day and steroid ointment in the evening. Dosing schedule will vary depending on the case presentation. The treatment for SLK is generally more involved and can require thermocautery, conjunctival resection or chemical cauterization with silver nitrate solution.

### References

1. Sweeney DF, Sankaridurg PR, Holden B, et al. A typical presentation of contact lens induced peripheral ulcers—multiple focal corneal infiltrates. ARVO poster 2002.
2. Aasuri MK, Wenkata N, Kumar Vm. Differential diagnosis of microbial keratitis and contact lens-induced peripheral ulcer. *Eye Cont Lens* 2003;29: S60-62.
3. Diec J, Carnt N, Tilia D, et al. Prompt diagnosis and treatment of microbial keratitis in a daily wear lens. *Optom Vis Sci* 2009; 86(7):E904-07.
4. 2007 Report of the International Dry Eye Workshop (DEWS). *The Ocular Surface* 2007; 5(2):75-88.
5. Fonseca EC, Arruda GV, Rocha EM. Dry eye: etiopathogenesis and treatment. *Arq Bras Oftalmol* 2010;73:197-203.
6. American Academy of Ophthalmology. Preferred practice pattern: dry eye syndrome. [www.aao.org/education/guidelines/ppp/upload/Dry\\_Eye\\_Syndrome-2.pdf](http://www.aao.org/education/guidelines/ppp/upload/Dry_Eye_Syndrome-2.pdf).
7. Perry HD. Dry eye disease: Pathophysiology, classification and diagnosis. *Am J Manag Care* 2008;14:S79-S87.
8. Behrens et al. Dysfunctional Tear Syndrome: A Delphi Approach to Treatment Recommendations. *Cornea* 2006; 25(8):900-07.
9. Lemp MA. Management of dry eye. *Am J Manag Care*. 2008;14:S88-S10.
10. Gumus K, Cavanagh DH. The role of inflammation and antiinflammation therapies in keratoconjunctivitis sicca. *Clin Ophthalmol* 2009;3:57-67.
11. Quinto GG, Campos M, Behrens A. Autologous serum for ocular surface diseases. *Arq Bras Oftalmol* 2008;71(6 Suppl):47-54.
12. Chang JH, McCluskey PJ, Wakefield D. Acute anterior uveitis and HLA-B27. *Surv Ophthalmol* 2005;50:364-88.
13. Hogan MJ, Kimura SJ, Thygeson P. Signs and symptoms of uveitis. *Am J Ophthalmol* 1959;47:155-70.
14. Gutteridge IF, Hall AJ. Acute anterior uveitis in primary care. *Clin Exp Optom* 2007;90:70-82.
15. Yanoff M, Duker JS, eds. *Ophthalmology*, 3rd ed. Maryland Heights, MO, Elsevier, 2009.
16. Ehlers JP, Shah CP, eds. *The Wills Eye Manual: Office and Emergency Room Diagnosis and Treatment of Eye Disease*, 5th Ed. Philadelphia, PA: Lippincott, Williams and Wilkins, 2008.